



HAL
open science

Identification of a new pharyngeal mucosal lymphoid organ in zebrafish and other teleosts: tonsils in fish?

J Resseguier, M Nguyen-Chis, J Wohlmann, D Rigaudeau, I Salinas, S H Oehlers, G F Wiegertjes, F E Johansen, S W Qiao, E O Koppang, et al.

► To cite this version:

J Resseguier, M Nguyen-Chis, J Wohlmann, D Rigaudeau, I Salinas, et al.. Identification of a new pharyngeal mucosal lymphoid organ in zebrafish and other teleosts: tonsils in fish?. 2024. hal-04494639

HAL Id: hal-04494639

<https://uvsq.hal.science/hal-04494639v1>

Preprint submitted on 7 Mar 2024

HAL is a multi-disciplinary open access archive for the deposit and dissemination of scientific research documents, whether they are published or not. The documents may come from teaching and research institutions in France or abroad, or from public or private research centers.

L'archive ouverte pluridisciplinaire **HAL**, est destinée au dépôt et à la diffusion de documents scientifiques de niveau recherche, publiés ou non, émanant des établissements d'enseignement et de recherche français ou étrangers, des laboratoires publics ou privés.

1 *Identification of a new pharyngeal mucosal lymphoid organ in zebrafish and*
2 *other teleosts: tonsils in fish?*

3
4 **AUTHORS**

5 *RESSEGUIER J*^{1*}, *NGUYEN-CHI M*^{2†}, *WOHLMANN J*^{3†}, *RIGAUDEAU D*⁴, *SALINAS I*⁵,
6 *OEHLERS SH*⁶, *WIEGERTJES GF*⁷, *JOHANSEN FE*⁸, *QIAO SW*⁹, *KOPPANG EO*¹⁰, *VERRIER B*¹¹,
7 *BOUDINOT P*^{12‡} and *GRIFFITHS G*^{8‡}.

8 † These authors contributed equally

9 ‡ These authors contributed equally

10 *Affiliations:*

11 ¹ *Section for Physiology and Cell Biology, Departments of Biosciences and Immunology, University of Oslo,*
12 *Oslo, Norway.*

13 ² *LPHI, CNRS, Université de Montpellier, Montpellier, France*

14 ³ *Electron-Microscopy laboratory, Departments of Biosciences, University of Oslo, Oslo, Norway.*

15 ⁴ *INRAE, Université Paris-Saclay, IERP, 78350 Jouy-en-Josas, France*

16 ⁵ *Center for Evolutionary and Theoretical Immunology (CETI), Department of Biology, University of New*
17 *Mexico, Albuquerque, NM, United States.*

18 ⁶ *A*STAR Infectious Diseases Labs (A*STAR ID Labs), Agency for Science, Technology and Research*
19 *(A*STAR), 8A Biomedical Grove, Immunos #05-13, Singapore 138648, Singapore*

20 ⁷ *Aquaculture and Fisheries Group, Department of Animal Sciences, Wageningen University & Research,*
21 *Wageningen, Netherlands*

22 ⁸ *Section for Physiology and Cell Biology, Department of Biosciences, University of Oslo, Oslo, Norway.*

23 ⁹ *Department of Immunology, Institute of Clinical Medicine, University of Oslo, Oslo, Norway.*

24 ¹⁰ *Unit of Anatomy, Faculty of Veterinary Medicine, Norwegian University of Life Sciences, Ås, Norway*

25 ¹¹ *Laboratory of Tissue Biology and Therapeutic Engineering, UMR 5305, IBCP, CNRS, University Lyon 1,*
26 *Lyon, France*

27 ¹² *Université Paris-Saclay, INRAE, UVSQ, Virologie et Immunologie Moléculaires, Jouy-en-Josas, France.*

28 *Corresponding author:* Julien.resseguier@gmail.com

29
30 *One sentence summary:* A previously unreported lymphoid organ has been identified within the
31 pharyngo-respiratory tract of the zebrafish, and other teleost fish, providing new insights into the
32 immune system of teleost fish and the evolution of vertebrate immunology.

33
34 *Keywords:* NEMO, Lymphoid organ, Zebrafish, Immunology, Branchial cavity, Teleost, Lymphoid
35 network, ILT, ALT.

36

37

38

39 ABSTRACT

40 The constant exposure of the fish branchial cavity to aquatic pathogens must have driven local
41 mucosal immune responses to be extremely important for their survival. In this study, we used
42 a universal marker for T lymphocytes/natural killer cells (ZAP70) and advanced imaging
43 techniques to investigate the lymphoid architecture of the zebrafish branchial cavity. We
44 identified a new lymphoid organ, which we tentatively named “Nemausean Lymphoid Organ”
45 (NEMO), situated below the pharynx, and closely associated with gill lymphoid tissues. Besides
46 T/NK cells, NEMO is enriched in plasma/B cells and antigen-presenting cells embedded in a
47 network of reticulated epithelial cells. Presence of activated T cells and lymphocyte
48 proliferation but not V(D)J recombination or hematopoiesis, suggests a function as secondary
49 lymphoid organ. In response to infection, NEMO displays structural changes including the
50 formation of T/NK cells clusters. NEMO and gill lymphoid aggregates form a cohesive unit
51 within a lymphoid network that extends throughout the pharyngo-respiratory area. Collectively,
52 our findings reveal a new mucosal lymphoid organ reminiscent of mammalian tonsils that
53 evolved in fish. Importantly, NEMO could clearly be identified in multiple teleost fish families.

54

55 INTRODUCTION

56 The survival of pluricellular organisms requires defense mechanisms against infections at
57 barrier tissues, the interface between the environment and the host. The emergence of adaptive
58 immunity, approximately 500 million years ago, marked a significant milestone in the defense
59 against pathogens. Adaptive immunity is based on clonal selection of lymphocytes expressing
60 somatically diversified genes encoding Ag receptors. The production of lymphocytes, their
61 differentiation to naïve B or T cells, and the V(D)J recombination of genes encoding Ag
62 receptors, occur in primary lymphoid organs. Naive lymphocytes then circulate through the
63 bloodstream, and relocate to secondary lymphoid organs where adaptive immune responses are
64 initiated, leading to lymphocyte activation and establishment of long-lived protective
65 immunity. Both primary and secondary lymphoid organs are constitutive and develop at
66 predetermined locations (1). During evolution, the emergence of secondary lymphoid organs
67 has been essential in facilitating adaptive immune responses by providing an organizational
68 framework favoring the co-localization of antigens and antigen-specific lymphocytes, which is
69 necessary for the efficient induction of antibody-mediated responses (2). The evolution of
70 lymphoid structures and adaptive immunity among Vertebrates have been studied and discussed
71 over the last century (3–10). Surprisingly, despite teleost fish representing approximately half
72 of all vertebrate species (<http://www.iucnredlist.org>), their immune system has received little
73 attention which is particularly noteworthy given the importance of teleost fish as a vital food
74 source for humans and animals (<http://www.fao.org> – The state of the world fisheries and aquaculture
75 2022).

76 The basic components of the immune system of teleost fish share many similarities with
77 mammals (11–13). Most of the cells of the innate and adaptive immune systems characterized
78 in mammals have also been identified in different species of fish, including granulocytes (14),
79 innate lymphoid cells (15), T cells (16), B cells (17–19), and antigen-presenting cells such as
80 macrophages (20, 21). Key molecular mechanisms involved in the detection of pathogens (22)
81 and in the regulation of the immune responses (23) are also shared across jawed vertebrates.
82 Teleost fish possess two known primary lymphoid organs: the thymus, which is responsible for

83 the development and maturation of T cells. In fish, the thymus is composed of two separate
84 lobules, one on the roof of each gill chamber. The thymus of teleost fish is separated into cortex-
85 like and medulla-like regions, which are not always well-defined (24). The other primary
86 lymphoid organ is the kidney, a site where hematopoiesis occurs and where B cell precursors
87 develop. The anterior part of the teleost fish kidney, the pronephros (also named “Head-
88 kidney”), is also a prominent site of immune activity associated with secondary lymphoid organ
89 (25). However, in fish, it is the spleen that is considered as the main systemic secondary
90 lymphoid organ (26). Recent studies have also suggested that adipose tissues may serve as
91 additional secondary lymphoid structures (27). No lymph nodes nor tonsil equivalents have
92 been observed in teleost fish. Although no clear counterparts of mammalian germinal centers
93 have been identified in teleost fish, the stimulation of the fish immune system can induce the
94 appearance of structures such as granulomas (28) and melano-macrophage centers (29).

95 In both fish and mammals, mucosal tissues provide an extensive surface that connects the
96 organism with the outside world. Mucosal tissues facilitate critical functions such as nutrient
97 absorption and gas exchange, however, such large surface area also increases exposure to
98 pathogens. As in mammals, fish mucosae are protected by multiple “Mucosa-Associated
99 Lymphoid tissues” (MALTs) which function in the immune surveillance of the mucosal
100 interface (30–32). The main fish MALTs are located in the gut (GALT), the skin (SALT), the
101 nostril (NALT), and the gills (GIALT) (33–36). In addition, recent studies have reported the
102 existence of a mucosal associated lymphoid tissue associated with the mouth and the pharynx
103 (37, 38). In mammals, the organization of MALTs is well-defined into regions where
104 disorganized immune cells are scattered, hence forming a diffuse mucosal immune system, and
105 into organized lymphoid aggregates such as Peyer’s patches in the gut and the Waldeyer’s ring
106 of tonsils of the nasopharyngeal area (39). In contrast, the organization of the fish mucosal
107 immune system has long been perceived as a set of scattered immune cells spread along
108 mucosal territories (18, 30, 40). However, such an organization of the immune system would
109 be difficult to reconcile with the evolutionary pressures exerted by the high concentration of
110 microbes in aquatic environments (41). One might intuitively expect the organization of the
111 fish immune system to be highly sophisticated. In fact, the absence organized lymphoid
112 structures in teleost fish has been challenged by recent discoveries, such as the identification of
113 the interbranchial lymphoid tissue (ILT) within the gills of Atlantic salmon (*Salmo salar*) in
114 2008 (42). This caused a severe breach within the paradigm of fish having a simple immune
115 system, opening up the need for further investigations of the fish lymphoid organization.

116 In order to further characterize the mucosal lymphoid organization of teleost fish, we took
117 advantage of the zebrafish as a research model system (43). It can be argued that the immune
118 system of the zebrafish is one of the best characterized among teleost fish. It is also ideally
119 suited for imaging, for whole-organism investigations, and benefits greatly from numerous
120 molecular tools, including many publicly available genetically-modified strains. The zebrafish
121 is also an established animal model to study human diseases and immune mechanisms (11, 44–
122 47), as well as an excellent model system to understand mechanisms relevant for aquaculture
123 (48).

124 In a previous study (36), using high-resolution 3D imaging of the zebrafish gills we
125 characterized the organization of the gill-associated lymphoid tissue (GIALT) and identified its
126 compartmentalization into segments where immune cells are unorganized, and two lymphoid
127 aggregates that display features of secondary lymphoid organs: the ILT and a newly identified

128 lymphoid tissue that we called the amphibranchial lymphoid tissue (ALT). These findings
129 revealed a higher degree of organization of fish MALTs and support our contention that there
130 is still much to learn about the organization of the fish immune system. This is particularly true
131 for the branchial cavity (also named gill chambers or pharyngeal cavities), which represents
132 one of the least understood parts of the fish anatomy despite its importance for many critical
133 functions such as breathing and ionic homeostasis. The branchial cavity in fact represents a
134 huge interface that is constantly accessible to water-borne microorganisms and debris. It also
135 contains essential immune structures, including the thymus and gill lymphoid tissues. The
136 branchial cavity consists of two chambers, one on each side of the head, that are bridged by the
137 pharynx in the middle and are open to the outside *via* the operculum slits. The region below the
138 pharynx that separates the gill chambers is called pharyngeal isthmus. Depending on the fish
139 species, the gill chambers can be entirely separated from each other, connected only *via* the
140 pharynx, as in zebrafish, or they can also merge below the pharyngeal isthmus, such as in
141 Atlantic salmon (49). The whole branchial cavity is lined by a non-keratinized squamous
142 “pharyngeal” epithelium (8, 50), which will be named “cavo-branchial epithelium” in the
143 present study to distinguish it from the histologically distinct epithelium that covers the
144 pharynx. Finally, each zebrafish gill chamber displays a set of four gill arches that connect the
145 anterior sub-pharyngeal region to the upper area of the branchial cavity, with each gill arch
146 bearing two ALTs and one ILT (36). The overall anatomy of the branchial cavity and the gills
147 are illustrated in **Figure S1** and **Figure S2**.

148 In order to investigate the whole branchial cavity, we used cryosections of adult zebrafish heads
149 in which we labeled tissue structures with fluorescent probes and then identified lymphoid
150 structures using an antibody targeting a highly conserved epitope of the kinase ZAP70, a marker
151 of T/NK cells. Our observations revealed a prominent lymphoid organ along the sub-pharyngeal
152 region of the branchial cavity that to the best of our knowledge had not been previously
153 described, and which we named the “Nemausean Lymphoid Organ” (NEMO).

154

155 **RESULTS**

156 **Identification of the Nemausean Lymphoid organ, a new lymphoid structure inside the** 157 **branchial cavity.**

158 As the zebrafish branchial cavity constitutes a complex anatomical territory, in order to
159 investigate this region in its entirety we conducted high-resolution 3D multi-fields of view
160 imaging of whole branchial cavity cryosections (30 μ m) from adults. These sections were
161 stained with fluorescent phalloidin to label F-actin and DAPI to stain DNA, facilitating the
162 identification of tissue structures. We focused on the immunolabeling of “Zeta-chain-associated
163 protein kinase 70 (ZAP70), a T cell / Natural Killer (NK) cell marker (51), to reveal the
164 organization of lymphoid tissues. The anti-ZAP70 antibody was used extensively in our earlier
165 studies, and has a good affinity across many species (36, 52). Additional evidences of its
166 specificity are presented **Fig.S3**.

167 During our initial exploration of the lower region of the branchial cavity using cryosections of
168 healthy adult wild-type (wt) zebrafish at various orientations (Fish N=10) (**Fig.1 A**), we found
169 a previously undescribed mucosal lymphoid organ below the pharynx, at the convergence of
170 the gill arches with the sub-pharyngeal isthmus. We tentatively named it “Nemausean
171 Lymphoid Organ” (NEMO) inspired by the Gallic-Roman “Nemausus - Nemausicae”

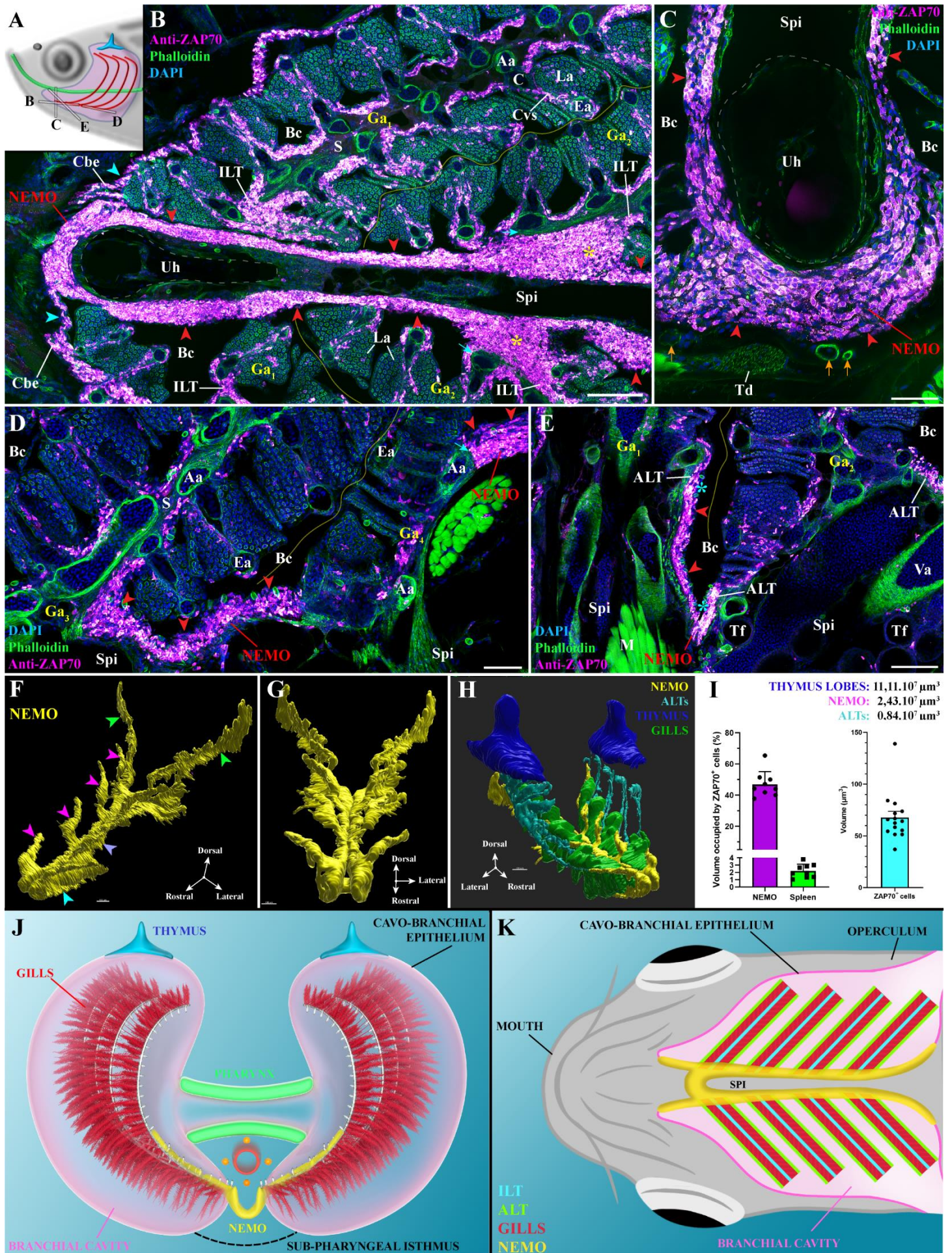
172 mythology associated with protection, water, and healing. NEMO was present in all analyzed
173 fish.

174 Analysis of the cryosections revealed that NEMO constitutes a large structure enriched in
175 ZAP70-positive cells located within the squamous mucosal epithelium lining the sub-
176 pharyngeal isthmus, a region under the pharynx that separates the two gill chambers (**Fig.1 B-
177 E** – red arrowheads). NEMO wraps around the urohyal bone at the anterior end of the branchial
178 cavity (**Fig.1 B,C**), joining the two gill chambers, before extending along each sides of the sub-
179 pharyngeal isthmus until it reaches the posterior end of the branchial cavity (**Fig.1 D**). Along
180 its length, NEMO is connected to all the twenty-four gill lymphoid aggregates: the eight ILTs
181 (**Fig.1 B** – yellow stars) and sixteen ALTs (**Fig.1 E** – cyan stars). Intriguingly, we could not
182 define any clear separation between ILT/ALT and NEMO at these connection sites, suggesting
183 that lymphoid structures of the branchial cavity may function as a single integrated unit. This
184 could have important implications regarding the role of the branchial cavity for the fish
185 immunity and its development. Other images displaying NEMO and its direct connection with
186 gill lymphoid aggregates are shown in **Fig.S4 A-D**. In addition, the expression of the kinase
187 Lck gene, another T cell marker, was investigated using *Tg(lck:EGFP)(16)* transgenic adult
188 zebrafish line and confirmed the presence of a large reservoir of T/NK cells along the sub-
189 pharyngeal region of the branchial cavity (**Fig.S4 E,F**).

190

191 **3D structure of NEMO**

192 These data indicated that NEMO exhibits a sophisticated architecture that is difficult to fully
193 capture from cryosections. We therefore built a more accurate reconstruction of NEMO's
194 structure in three-dimensions by adapting our imaging approach from cryosections to whole
195 young adult wild-type zebrafish heads (15 weeks post-fertilization (wpf)) to reveal the
196 distribution of T/NK cells within the whole branchial cavity area using serial confocal
197 tomography. This automated technique combines sectioning with a vibratome and imaging with
198 a confocal microscope using a robot. This approach enabled the assembly of a NEMO 3D
199 structure from over 700 imaged layers, thereby defining NEMO boundaries using the
200 distribution of the ZAP70 signal (**Fig.1 F,G**). This accurate representation revealed the
201 segmentation of NEMO into four distinct anatomical sub-regions: 1. The anterior-most region
202 that wraps around the urohyal bone (**Fig.1 F** – cyan arrowhead) 2. The four “antler-like”
203 protrusions that each connect with two ALTs (**Fig.1 F** – magenta arrowheads) 3. The core that
204 extends along the sub-pharyngeal isthmus (**Fig.1 F** – blue arrowhead), and 4. The posterior end
205 that starts after the 4th set of gill arches and extends toward the operculum opening (**Fig.1 F** –
206 green arrowheads). Further research will be required to determine the degree of tissue
207 homogeneity between these four segments. The 3D reconstruction of the thymus lobes (blue),
208 the sixteen ALTs (cyan), and the ventral extremity of the eight gill arches (green) allowed us to
209 interpret NEMO (yellow/magenta) in the spatial context of the fish, and in particular of the
210 branchial cavity (**Fig.1 H, Video.S1-S4**). This approach illustrated clearly the localization of
211 NEMO along the ventral axis of the fish head. Furthermore, this global reconstruction further
212 highlighted the continuity between NEMO antler-like protrusions with all ALTs. The
213 localization of NEMO within the branchial cavity is further illustrated **Fig.1 J,K**.



215 **Figure 1 – General organization and localization of the adult zebrafish NEMO.** (A) Scheme illustrating the
216 different orientations of the adult zebrafish NEMO images acquired from 30 μm whole-head cryosections, and
217 which highlight the position of the thymus (blue), pharynx (green), and gills (red). (B-E). NEMO (red arrowheads)
218 wraps around the urohyal bone (B,C), and extends along the sub-pharyngeal isthmus toward the posterior end of
219 the gill chambers (D). NEMO is connected to the interbranchial lymphoid tissues (B - yellow stars), the
220 amphibranchial lymphoid tissues (E – cyan stars), and the cavobranchial epithelium (A - cyan arrowheads). NEMO
221 is in close proximity to gills afferent arteries (B – cyan arrows) and other endothelial vessels (C - orange arrows).
222 (F-G) NEMO 3D reconstruction obtained with serial confocal tomography of a ZAP70-labeled wholemount head
223 of zebrafish (15 wpf), revealing a segmentation into 4 anatomic regions: the front end wrapped around the urohyal
224 bone (cyan arrowhead), antler-like protrusions (magenta arrowheads), the core (blue arrow), and the posterior end
225 (green arrowheads). (H) 3D reconstruction of NEMO (yellow), ALTs (cyan), thymus lobes (blue) and the ventral
226 end of gill arches (green). (I) Volumes of different lymphoid structures from the 3D reconstruction, average
227 volume occupied by T/NK cells in NEMO and the spleen, and average volume of a single T/NK cell. (J,K)
228 Simplified illustrations of NEMO's localization within the branchial cavity, as observed from the front (J) or from
229 below (K). Illustrations made by Ella maru studio and K.Zulkefli. Annotations: Aa, Afferent artery; ALT,
230 Amphibranchial lymphoid tissue; Bc, Branchial cavity; C, Cartilage; Cbe, Cavo-branchial epithelium; Cvs, Central
231 venous sinus; Ea, Efferent artery; Ga, Gill arch; ILT, Interbranchial lymphoid tissue; La, Lamellae; M, Muscles;
232 NEMO, Nemausean lymphoid organ; S, Septum; Spi, Sub-pharyngeal isthmus; Td, Tendon; Tf, Thyroid follicle;
233 Uh, Urohyal bone and Va, Ventral aorta. Scale bars: 150 μm (H), 100 μm (B, E-G), 50 μm (D), and 40 μm (C).

234 We then estimated the volume of NEMO based on the 3D reconstruction shown in **Fig.1**. In
235 this 15 wpf zebrafish NEMO had a volume of $2.4 \times 10^7 \mu\text{m}^3$, which is smaller than the thymus
236 ($11.1 \times 10^7 \mu\text{m}^3$; $5.5 \times 10^7 \mu\text{m}^3$ and $5.6 \times 10^7 \mu\text{m}^3$ for each lobe); at this stage, the thymus has just
237 started to involute. Using a stereology approach and 3D reconstruction, we estimated that T/NK
238 cells occupy 46,8% of NEMO's volume (Sections: N=9 obtained from 3 fishes) for an average
239 volume of $67,7 \mu\text{m}^3$ per ZAP70-positive cells (3D reconstructed cells: N=15 obtained from 3
240 fishes) (**Fig.1 I**). In this 15 wpf zebrafish, NEMO would then contain around 165 000 T/NK
241 cells. In comparison, the number of spleen T/NK cells, assessed using a similar approach
242 (Sections: N=9 obtained from 3 fishes) and a rough estimation of the spleen volume, was around
243 120 000 T/NK cells (2,2% of the spleen's volume). Noteworthy, the overall volume of the
244 sixteen ALTs was estimated to be $0.84 \times 10^7 \mu\text{m}^3$, therefore indicating that the ALTs represent
245 much smaller structures compared to NEMO. Collectively, these data indicate that NEMO
246 constitutes a prominent structure of the branchial cavity, and provide a first line of evidence
247 that it constitutes a separate organ. Furthermore, the central position of NEMO along the two
248 branchial cavity and at their junction suggest an ideal localization for NEMO to be an immune
249 site centralizing immune functions protecting the branchial cavity.

250

251 **NEMO is a mucosal lymphoid organ**

252 The next objective was to determine whether the structural organization of NEMO at the
253 cellular level is consistent with the known organization of lymphoid organs and tissues. A
254 hallmark of structured lymphoid aggregates, such as the thymus, lymph nodes, Peyer's patches
255 or tonsils in mammals is the characteristic arrangement of the immune cells within a meshwork
256 of reticulated epithelial cells that acts as an immuno-platform (53, 54). This feature was a key
257 element in classifying teleost fish ILT and ALT as lymphoid tissues (36, 55). We therefore
258 labeled cryosections of NEMO with a commonly used cocktail of antibodies to reveal
259 cytokeratins, which are essential constituents of the reticulated epithelial cell cytoskeleton. A
260 complex network of reticulated epithelial cells was found at the boundaries (red arrowheads)
261 and within (yellow arrowheads) the anterior segment of NEMO (**Fig.2 A**). Further analysis
262 confirmed that this network of reticulated epithelial cells extended throughout NEMO in its
263 entirety (**Fig.S5 A,B**). 3D reconstruction of the cytokeratin signal revealed that the arrangement
264 of reticulated epithelial constitutes organized pockets of cells that are typical of lymphoid
265 aggregates (**Fig.2 B – Video.S5**). Noteworthy, NEMO reticulated epithelial cells display a low

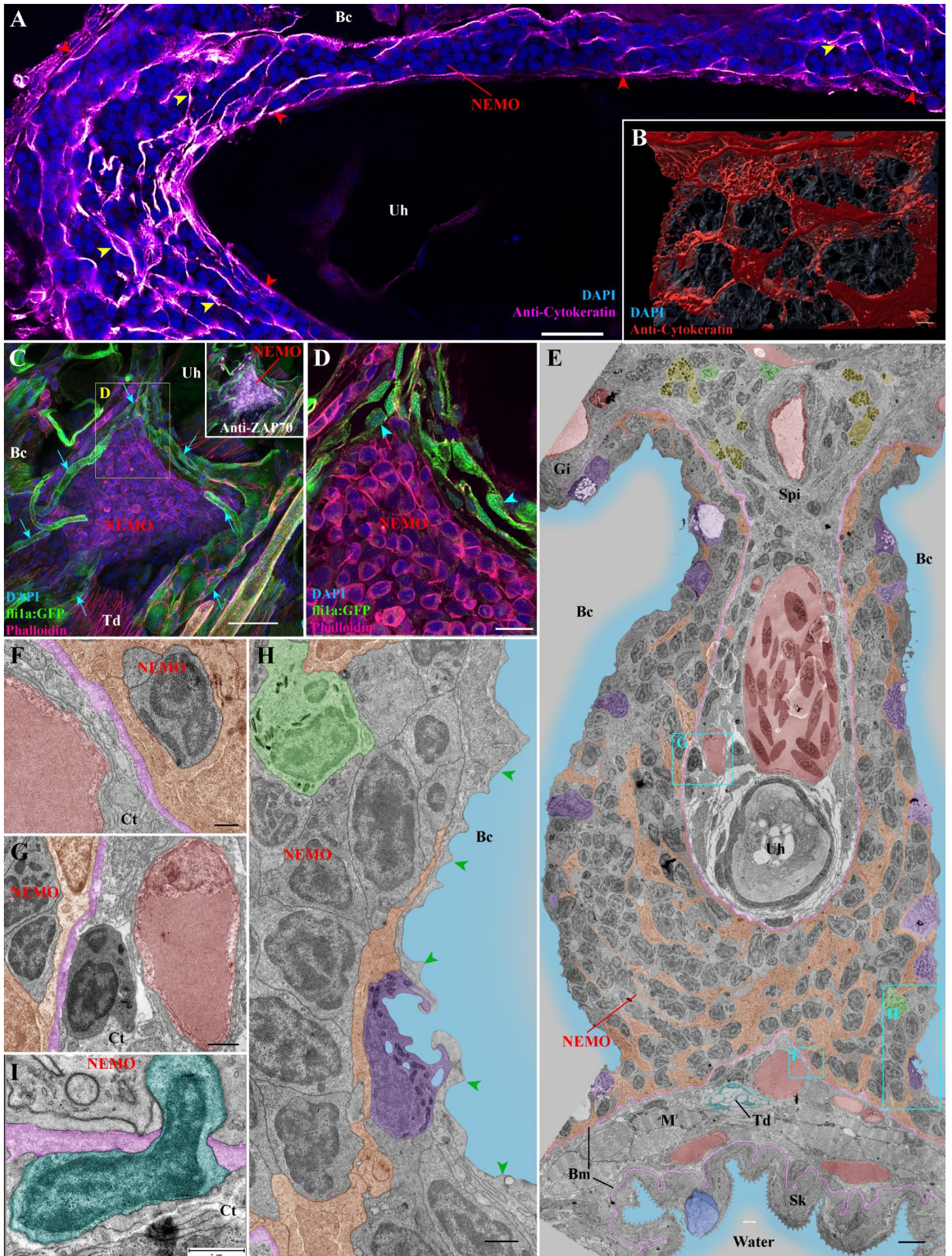
266 expression of the MHC-class II gene *mhc2dab* (**Fig.S5 C-F**) and are connected with each
267 other's by hemi-desmosome (**Fig.S5 G** – cyan arrow). Both these features are shared by the
268 reticulated epithelial cells of mammalian lymphoid aggregates (53, 56).

269 In order to sustain their functions, lymphoid organs require access to oxygen and nutrient
270 supply, as well as mechanisms to facilitate immune cell trafficking. The localization of NEMO
271 in close proximity to inhaled water ensures a continuous oxygen supply. The circulatory system
272 functions as a conduit for nutrient delivery and immune cell trafficking throughout the body.
273 The next question was to determine if NEMO is vascularized using 3D imaging of cryosections
274 from an adult zebrafish line in which both vascular and lymphatic endothelial cells express a
275 fluorescent protein (*Tg(fli1a:EGFP)* (57)). Although no endothelial structures were found
276 within NEMO, numerous endothelial vessels were observed surrounding it (**Fig.2 C** – cyan
277 arrows, **Video.S6**). This finding is consistent with the phalloidin staining, which strongly labels
278 the smooth muscles surrounding blood vessels, observed in **Fig.1 C** (orange arrows). Opening
279 up the 3D stacks to look at the optical sections, we found that some of the narrow vessels
280 surrounding NEMO were lined by cuboidal endothelial cells (**Fig.2 D** – cyan arrowheads),
281 which sometimes line fish arteries and heart endocardium (58). However, we could not detect
282 around these particular vessels the characteristic layer of smooth muscles that usually surrounds
283 fish arteries. In humans, cuboidal endothelial cells are a hallmark of the high-endothelial
284 venules that are characteristic of mammalian lymph nodes and tonsils (59). Further studies will
285 have to determine if the vessels wrapping around NEMO constitute blood vessels, conventional
286 lymphatic vessels or the non-conventional blood/lymphatic “fine” vessels that were first
287 reported in cod almost a century ago by Burne (60). In addition to the previously described
288 vessels, NEMO also benefit from a close proximity with the prominent gill vasculature at its
289 convergence with the gill lymphoid aggregates (**Fig.1 B,D** – cyan arrows).

290

291

292 **Figure 2 – Detailed structural organization of the adult zebrafish NEMO.** (A) NEMO cryosections labeled with
293 anti-cytokeratin antibodies (magenta hot) revealing a network of reticulated epithelial cells within (yellow
294 arrowheads) and bordering NEMO (red arrowheads). (B) 3D reconstruction illustrating the network of reticulated
295 epithelial cells in red. (C) 3D imaging of NEMO cryosections from *fli:GFP* zebrafish, in which endothelial vessels
296 are fluorescent (green). Numerous vessels are wrapped around NEMO (cyan arrows). (D) Optical section from (C)
297 highlighting cuboidal-shaped endothelial cells (cyan arrowheads). (E-H) Ultrastructure map of a 9 wpf zebrafish
298 NEMO transversally sectioned at the urohyal bone acquired by transmission electron microscopy. Several
299 structures have been highlighted: Reticulated epithelial cells (orange), mucous cells (dark blue), water (light blue),
300 ionocytes (purple), endothelial vessels (burgundy red), basement membrane (pink), neutrophils (green),
301 basophils/mast cells (yellow), tenocytes (dark blue-green), and pavement cells (green arrowheads). (F-H) represent
302 zoomed area from (E). (I) Cell (dark blue-green) observed across the basement membrane (pink) separating NEMO
303 from the surrounding connective tissue. Annotations: Bc, Branchial cavity; Bm, Basement membrane; Gi, Gills;
304 M, Muscles; Sk, Skin; Spi, Sub-pharyngeal isthmus; Td, Tendon and Uh, Urohyal bone. Scale bars: 30 μm (C), 20
305 μm (A), 10 μm (D), 4 μm (E), 3 μm (B), 1 μm (G,H,I), and 500 nm (F).



307 **Ultrastructure of NEMO**

308 In order to continue our investigation of NEMO at a higher resolution we used transmission
309 electron microscopy (TEM) of ultrathin sections and a new data browsing method developed
310 by Jens Wohlmann (manuscript in preparation) to easily access ultrastructural images at
311 different scales over a large area. This method overcomes the challenge of analyzing complex
312 ultrastructure of tissues at different magnifications, especially when one needs to switch from
313 low to high-magnification in a smooth manner. Such a dynamic ultrastructure map allows the
314 user to efficiently navigate within the biological sample. Using this approach, we assembled a
315 detailed map (>1400 micrographs) covering a significant portion of NEMO's anterior segment
316 in a 9 weeks post-fertilization juvenile zebrafish (**Fig.2 E**).

317 The EM data highlighted a number of striking features and provided additional insights into
318 NEMO. The network of reticulated epithelial cells was prominent (orange) and the nuclei of
319 these cells were much less electron-dense and more elongated than the nuclei of the neighboring
320 cells (**Fig.2 E, Fig.S5 G**). EM analysis confirmed the close proximity of NEMO to neighboring
321 endothelial vessels (burgundy red), which were mostly separated by a thin basement membrane
322 (pink) that forms a boundary between NEMO and the surrounding connective tissue (**Fig.2 F-
323 G**). These observations support our view that NEMO constitutes a distinguishable entity. The
324 ultrastructure map shows unequivocally that NEMO is only separated from the outside
325 environment by a single layer of epithelial cells (**Fig.2 H**). These cells were predominantly
326 pavement cells, which can be identified by their elongated shape and characteristic actin
327 microridges (green arrowheads). Interspersed between pavement cells were mitochondria-rich
328 cells (ionocytes) (**Fig.2 E,H** - purple). This squamous mucosal epithelium is reminiscent of the
329 epithelium that lines the gills (61), which suggests they may share a similar developmental
330 origin. The EM analysis also revealed the presence of cells that have penetrated the basement
331 membrane bordering NEMO (**Fig.2 I** – cyan), indicating the existence of a cell traffic in or out
332 of NEMO.

333 Intriguingly, whereas the thymus lobes are already present in 3 days post-fertilization zebrafish
334 (62), we could not detect NEMO in 3 wpf zebrafish (not shown). Moreover in the 9 wpf
335 juveniles we used in our ultrastructure investigation, NEMO was present but we failed to detect
336 ILT or ALT. Looking at a publicly available atlas of zebrafish paraffin section stained with
337 H&E (<https://bio-atlas.psu.edu/zf/progress.php>), we could identify structures reminiscent of
338 NEMO in 6-7 wpf zebrafish, suggesting NEMO ontogeny would start between the 4th and the
339 6th week of development.

340 Collectively, our findings from both light and electron microscopy lead us to propose that
341 NEMO is a new constitutive mucosal lymphoid organ in fish that is associated to the branchial
342 cavity.

343

344 **NEMO is a lymphoid organ highly enriched with both B and T cells.**

345 Based on a T/NK cells marker (ZAP70), we defined NEMO as a mucosal lymphoid organ and
346 described its location in the gill chamber area, the obvious next question was: What role does
347 it play in the fish immune system? In order to address this question we first investigated the
348 diversity of its immune cell populations in adult zebrafish. Our electron microscopy analysis
349 revealed a small number of neutrophils, identified by their typical elongated granules (**Fig.2
350 E,H** - green). Their presence was confirmed by confocal microscopy using zebrafish in which
351 neutrophils express fluorescent proteins (*Tg(mpx:GFP)* (63)) (**Fig.3 A**). Also by TEM, fish
352 basophils/mast cells, which displayed characteristic large spherical electron-dense granules,

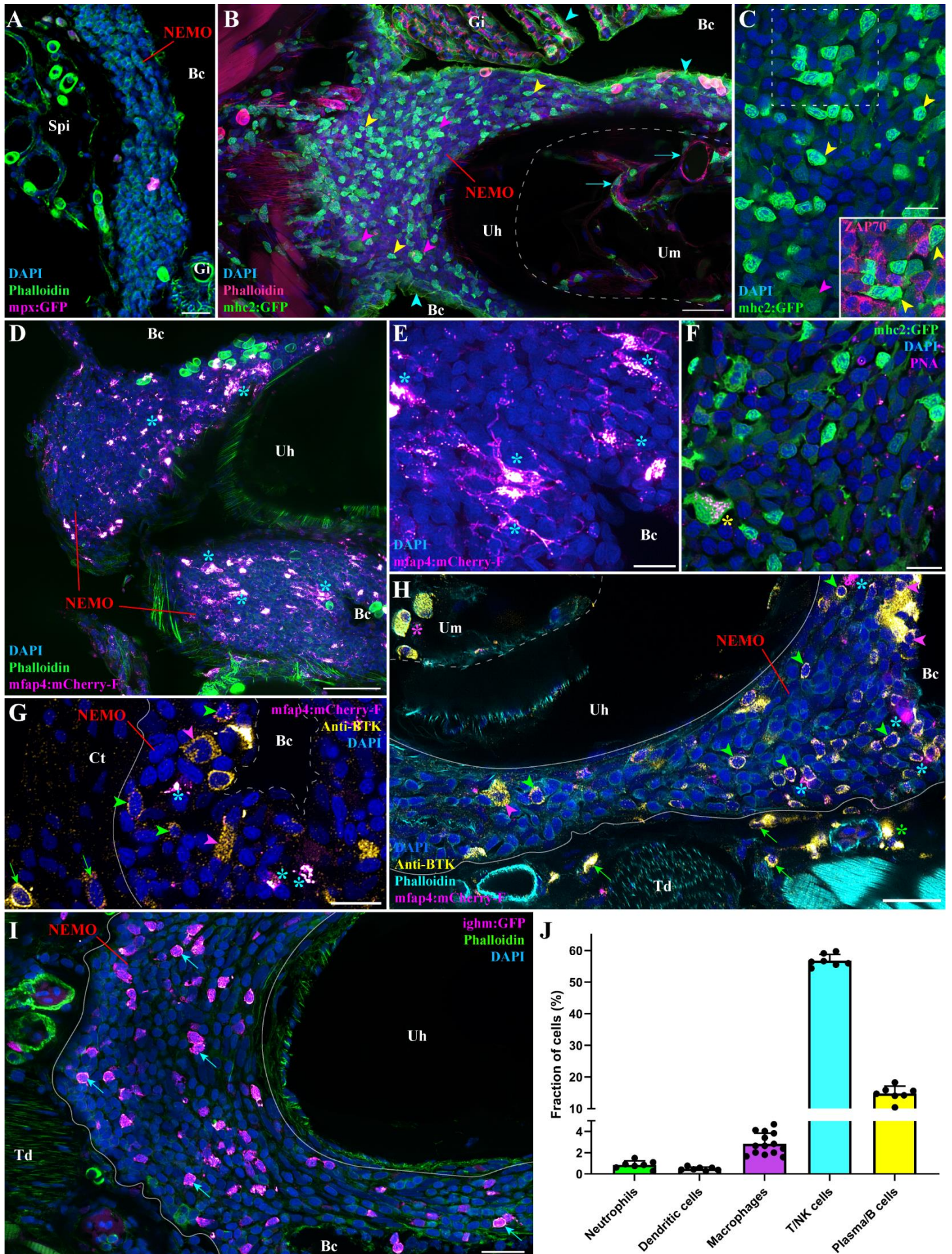
353 were evident within the connective tissues adjacent to NEMO; however we did not observe any
354 of these cells or eosinophils within NEMO itself (**Fig.2 E** –yellow).

355 We next investigated the presence of antigen-presenting cells in NEMO using
356 *Tg(mhc2dab:GFP)* (64) adult zebrafish (**Fig.3 B,C**). Consistent with previous studies (36, 64),
357 we observed expression of the transgene in epithelial cells (cyan arrowheads), including the
358 *mhc2^{low}* reticulated epithelial cells. Noteworthy, *mhc2*-expressing cells associated to
359 endothelial structures were observed within the marrow of the urohyal bone (cyan arrows).
360 Within NEMO, the presence of large *mhc2⁺* cells (magenta arrowheads) suggested the presence
361 of macrophages and/or dendritic cells, which are so-called professional antigen-presenting
362 cells. Imaging of *Tg(mfap4:mCherry-F)* zebrafish (65), a zebrafish line in which macrophages
363 express a farnesylated membrane-associated fluorescent protein, revealed many large
364 fluorescent macrophages (**Fig.3 D,E** – cyan stars). We then labeled dendritic cells using a
365 fluorescent peanut-agglutinin lectin, as described in (36, 66) (**Fig.3 E** – yellow star). This
366 marker reveals a subset of large *mhc2⁺* cells with a striking labeling of cytoplasmic vesicles
367 (66). In addition to the large *mhc2* cells, we also observed numerous small lymphocyte-like
368 cells in NEMO that strongly expressed *mhc2* but were negative for ZAP70 (**Fig.3 B,C** – yellow
369 arrowheads).

370 Since B cells are usually known to lack ZAP70 and to express high amount of *mhc2* proteins
371 (51, 67), we hypothesized that these cells could belong to the B cell lineage. Similar to our
372 approach using a conserved epitope of ZAP70 to label T/NK cells, we then used a well-
373 characterized antibody against human Bruton Tyrosine Kinase (BTK), an essential constituent
374 of the B cell lineage (**Fig.3 G,H**) (68, 69). Since in humans BTK has also been shown to localize
375 in subsets of macrophages (70), we used this antibody on *mfap4:mCherry-F* zebrafish in order
376 to distinguish between macrophages and the B-cell lineage. The anti-BTK labeling revealed the
377 presence of many B-cells (green arrowheads) and plasma cells (magenta arrowheads) within
378 NEMO parenchyma, the adjacent connective tissue (green arrows), as well as in the marrow of
379 the urohyal bone (magenta star). Within the surrounding connective tissue, B cells and plasma
380 cells were often associated to endothelial structures (green star). Additional data on the anti-
381 BTK labeling are available **Fig.S6**, including the expression of *mhc2* by small BTK-positive
382 cells. The identification of B-cells in NEMO was confirmed by using the *Tg(Cau.Ighv-
383 ighm:EGFP)* transgenic line (**Fig.3 I** – cyan arrows) (71), in which a subset of B-cells
384 expressing IgM was selectively marked. Quantification of the different immune cell types in
385 NEMO is shown in **Fig.3 J** and confirmed the predominance of lymphoid cells in NEMO: T/NK
386 cells (56,8% of total cells), B cells (14,7%), whereas neutrophils, macrophages and dendritic
387 cells accounted for less than 5% of the total. The remaining 24% includes the reticulated
388 epithelial cells and the cells forming the squamous epithelial layer. Collectively, these data
389 support our contention that NEMO has characteristics predicted for a mucosal secondary
390 lymphoid organ. We emphasize that our analysis does not address all the cell types and cell
391 subsets present in NEMO. For this, additional molecular analyses, such as transcriptomics, are
392 needed.

393

394



396

397 **Figure 3 – NEMO immune cell population.** (A) Adult mpx:GFP zebrafish NEMO cryosection, in which
398 neutrophils are fluorescent (Magenta hot). (B) Adult mhc2:GFP zebrafish cryosection, in which mhc2-expressing
399 cells are fluorescent (green). Expression of MHC2 is observed in the epithelial cells (cyan arrowheads), large cells
400 inside NEMO (magenta arrowheads), and within the marrow of the urohyal bone (cyan arrows). (C) Zoom inside
401 NEMO of a mhc2:GFP fish highlighting large (magenta arrowheads) and small (yellow arrowheads) positive cells.
402 The latter being negative for anti-ZAP70 labeling (cherry). (D,E) Adult mfap4:mCherry-F zebrafish NEMO
403 cryosections, in which macrophages are fluorescent (magenta hot – cyan stars). (F) Cryosections of adult
404 mhc2:GFP zebrafish NEMO stained with peanut agglutinin lectin (magenta hot) to reveal dendritic cell (yellow
405 star). (G-H) Anti-BTK labeling (yellow hot) of mfap4:mCherry-F adult zebrafish cryosections revealed
406 macrophages (magenta hot – cyan stars) as well as both BTK-positive B cells (green arrowheads) and plasma cells
407 (magenta arrowheads) in NEMO. BTK-positive cells were also found in the connective tissue surrounding NEMO
408 (green arrows), around endothelial structures (green stars) and within the marrow of the urohyal bone (magenta
409 star). (I) The presence of B cells in NEMO was confirmed using ighm:GFP zebrafish, in which a subtype of B
410 cells that express IgM is fluorescent (magenta hot – cyan arrows). (J) Quantification of the different immune cell
411 population found in NEMO counted from at least 7 single-cell layers images originating from at least 3 fish.
412 Annotations: Bc, Branchial cavity; Gi, Gills; Spi, Sub-pharyngeal isthmus; Td, Tendon; Uh, Urohyal bone and
413 Um, Urohyal marrow. Scale bars: 50 μ m (D), 30 μ m (B), 20 μ m (A, H-I), and 10 μ m (C, E-G).

414

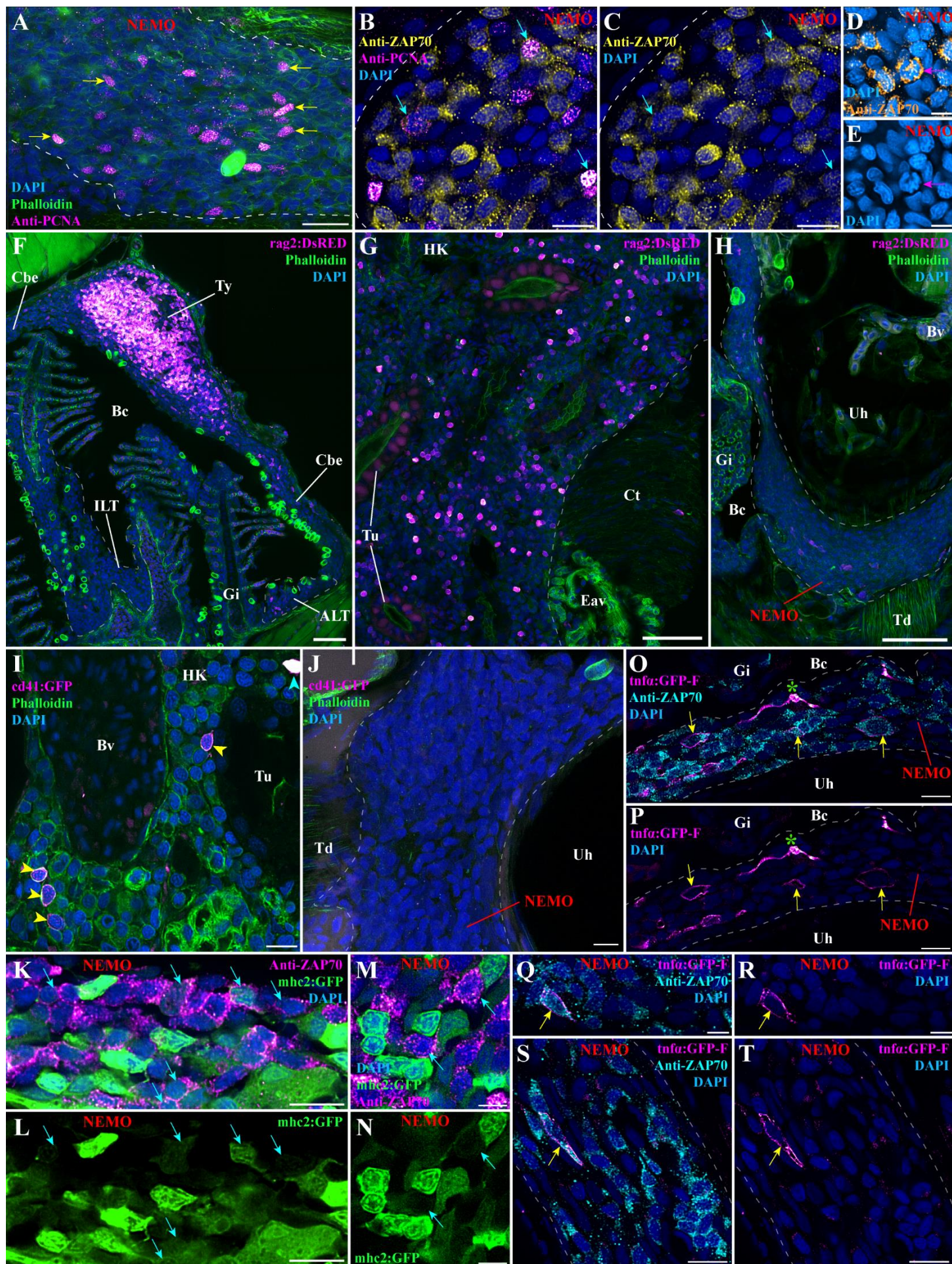
415 **Functional characterization of NEMO**

416 In order to further investigate the role of NEMO, we carried out an initial set of experiments to
417 address whether or not NEMO could be a primary lymphoid organ. We first determined cell
418 proliferation within NEMO using a labeling targeting the “proliferating cell nuclear antigen”
419 (PCNA), a protein that is selectively expressed by cells engaged in cell division. As evident in
420 **Fig.4 A** (yellow arrows), cell proliferation was prominent within NEMO. Many of the PCNA-
421 labeled cells were also positive for ZAP70 (**Fig.4 B,C** – cyan arrows). Consistent with this
422 result, we observed T/NK cells that displayed mitotic figures (**Fig.4 D,E** – magenta arrows).
423 By itself, the presence of T/NK cells proliferation is insufficient to distinguish between
424 secondary and primary lymphoid organs. Therefore, we investigated the presence of
425 mechanisms involved in the differentiation of lymphoid cells, which are hallmarks of primary
426 lymphoid organs such as the thymus and kidney in zebrafish.

427 The protein RAG2 is an enzyme required for V(D)J recombination that is expressed by
428 developing T cells in the thymus, and by developing B cells in the fish kidney. In order to
429 determine if NEMO is involved in lymphocyte development we used a zebrafish line with a
430 fluorescent reporter for rag2 expression (*Tg(rag2:DsRED)* (72)). In contrast to the typical high
431 expression of rag2 found in the thymus and the head-kidney, NEMO, like the ALT and ILT
432 (36, 73), did not show any significant expression of rag2 (**Fig.4 F-H**). This result argues that
433 NEMO does not have the primary lymphoid functions involved in B and T cell development,
434 nor is it an additional thymus.

435 In adult fish the production of immune cells by hematopoiesis occurs in the kidney. This process
436 involves hematopoietic stem cells that reside in the immune compartment of the kidney located
437 in-between the nephrons. In zebrafish these cells are identifiable by their low expression of the
438 protein CD41, while it is highly expressed by thrombocytes (fish analogue of platelets) (74). In
439 order to determine if NEMO represents an additional site of hematopoiesis, we used the
440 transgenic zebrafish line *Tg(cd41:GFP)*. Whereas the hematopoietic stem cells are evident
441 within the kidney (**Fig.4 I** – yellow arrowheads), we could not observe them in NEMO (**Fig.4**
442 **J**). Collectively, our data shows that NEMO is neither involved in lymphocyte V(D)J
443 recombination, nor in hematopoiesis, which constitutes a strong evidence that it is not a primary
444 lymphoid organ.

445



447 **Figure 4 – Investigation of immune function molecular markers in NEMO.** (A) NEMO cryosections labeled
448 with anti-PCNA antibody (magenta hot) to reveal cell proliferation (yellow arrows). (B-C) Cryosection co-labeled
449 with anti-PCNA (magenta hot) and anti-ZAP70 (yellow hot) to reveal the presence of proliferative T/NK cells in
450 NEMO (cyan arrows). (D-E) The presence of proliferative T/NK cells in NEMO was confirmed by the presence
451 of ZAP70-positive cells (orange hot) displaying mitotic figures (magenta arrow). (F-H) Cryosections from
452 rag2:DsRED zebrafish in which cells undergoing V(D)J recombination are fluorescent (magenta hot). Whereas
453 numerous positive cells are found in the thymus (F) and the head-kidney (G), which are known sites of V(D)J
454 recombination for T and B cells, almost none were observed in NEMO (H), ILTs and ALTs (F). (I,J) Cryosections
455 from cd41:GFP zebrafish, in which thrombocyte (cyan arrowhead) are brightly fluorescent and hematopoietic stem
456 cells are faintly fluorescent (yellow arrowhead) (magenta hot). In contrast to the expected localization of
457 hematopoietic stem cells in the kidney (I), none were observed in NEMO (J). (K-N) Cryosections from mhc2:GFP
458 zebrafish (green) labeled with anti-ZAP70 (magenta hot) revealed the presence of mhc2-expressing T/NK cells
459 (cyan arrows), a feature of activated T/NK cells. (O-T) Cryosections from tnfa:GFP zebrafish NEMO, in which
460 cells expressing the immune effector molecule TNF- α are fluorescent (magenta hot), labeled with anti-ZAP70
461 (cyan). Annotations: ALT, Amphibranchial lymphoid tissue; Bc, Branchial cavity; Bv, Blood vessel; Cbe,
462 Cavobranchial epithelium; Ct, Connective tissue; Eav, Endothelium anastomotic vessels; Gi, Gills; HK, Head-
463 kidney; ILT, Interbranchial lymphoid tissue; Td, Tendon; Tu, Tubule; Ty, Thymus and Uh, Urohyal bone. Scale
464 bars: 50 μ m (F-H), 20 μ m (A), 10 μ m (B-C, I-L, O-P, S-T), and 5 μ m (D-E, M-N, Q-R).

465 We next checked whether NEMO displayed features that are characteristic of lymphoid organs
466 involved in immune responses. During our investigation using *Tg(mhc2dab:GFP)* zebrafish we
467 found ZAP70-positive cells that were also MHC2-positive (**Fig.4 K-N** – cyan arrows); this
468 likely indicates the presence of activated T/NK cells in NEMO (75, 76). In addition, we also
469 observed ZAP70-positive cells expressing the effector molecule TNF α (77), using the zebrafish
470 line *Tg(tnfa:eGFP-F)* (78) (**Fig.4 O-T** – yellow arrows). Altogether, these results support the
471 concept of NEMO being a mucosal secondary lymphoid organ.

472

473 **Structural changes in NEMO in response to viral and parasitic infection.**

474 If NEMO is indeed a mucosal secondary lymphoid organ it would be expected to be involved
475 in immune responses to infections. Toward this goal, we first investigated zebrafish (N=3) that
476 were naturally co-infected in a zebrafish facility with three different parasites (*Pseudoloma*
477 *neurophilia*, *Pseudocapillaria tomentosa*, and *Myxidium streisingeri*) that respectively infect
478 the nervous system, the intestines, and the kidneys (79). In contrast to uninfected fish (**Fig.1,**
479 **Fig.S4**), the distribution of ZAP-positive cells appeared more heterogeneous and some of the
480 labelled cells formed small local clusters (cyan stars) (**Fig.5 A,B**). Noteworthy, we could also
481 observe an abundance of BTK-positive cells corresponding to B cells and plasma cells within
482 the connective tissue and associated to narrow endothelial vessels of the sub-pharyngeal
483 isthmus (**Fig.S7**). These changes gave the first hint of a structural rearrangement of NEMO in
484 response to long-term parasitic infection. Furthermore, as none of these parasites directly infects
485 the branchial cavity, it also reveals that NEMO's involvement in immune response is not
486 restricted to the branchial cavity but likely play a broader function in the overall defense of the
487 organism.

488 We next studied the effect of controlled bath-infection on NEMO using two well established
489 and commercially relevant fish pathogenic rhabdoviruses that infect tissues of the branchial
490 cavity: Infectious Hematopoietic Necrosis Virus (IHNV) (80, 81) and Spring Viraemia of Carp
491 Virus (SVCV) (82, 83). IHNV infection showed mild structural changes in NEMO at 3 dpi
492 (**Fig.5 E** – yellow stars) that were evident as a seemingly deeper aggregation of ZAP70-positive
493 cells into large clusters (yellow stars). A week later (10 dpi), these aggregates of cells had
494 reverted toward the usual distribution of ZAP70-positive cells observed in uninfected fish
495 (**Fig.5 F**). The effect of SVCV infection were more severe with the striking reorganization of
496 ZAP70-positive cells into distinct large clusters at 3 dpi (**Fig.5 E, Fig.S8** – yellow stars). By
497 10 dpi (**Fig.5 F**), more ZAP70-positive cells, as well as smaller clusters of labelled cells (cyan

498 star), were observed between the remaining large clusters (yellow star). When we labelled
499 sections from the 3 dpi SVCV-infected fish with an antibody against the N protein of the virus,
500 we detected labelled cells on the periphery of the large T/NK cells clusters (**Fig.5 G-J**). This
501 data confirmed that the fish were successfully infected by the virus. Whether or not these
502 labelled cells represent primarily infected cells or antigen-presenting cells that have taken-up
503 viral material remains to be established. Collectively, these data show the involvement of
504 NEMO in the organism response to viral pathogen infecting tissues of the branchial cavity.

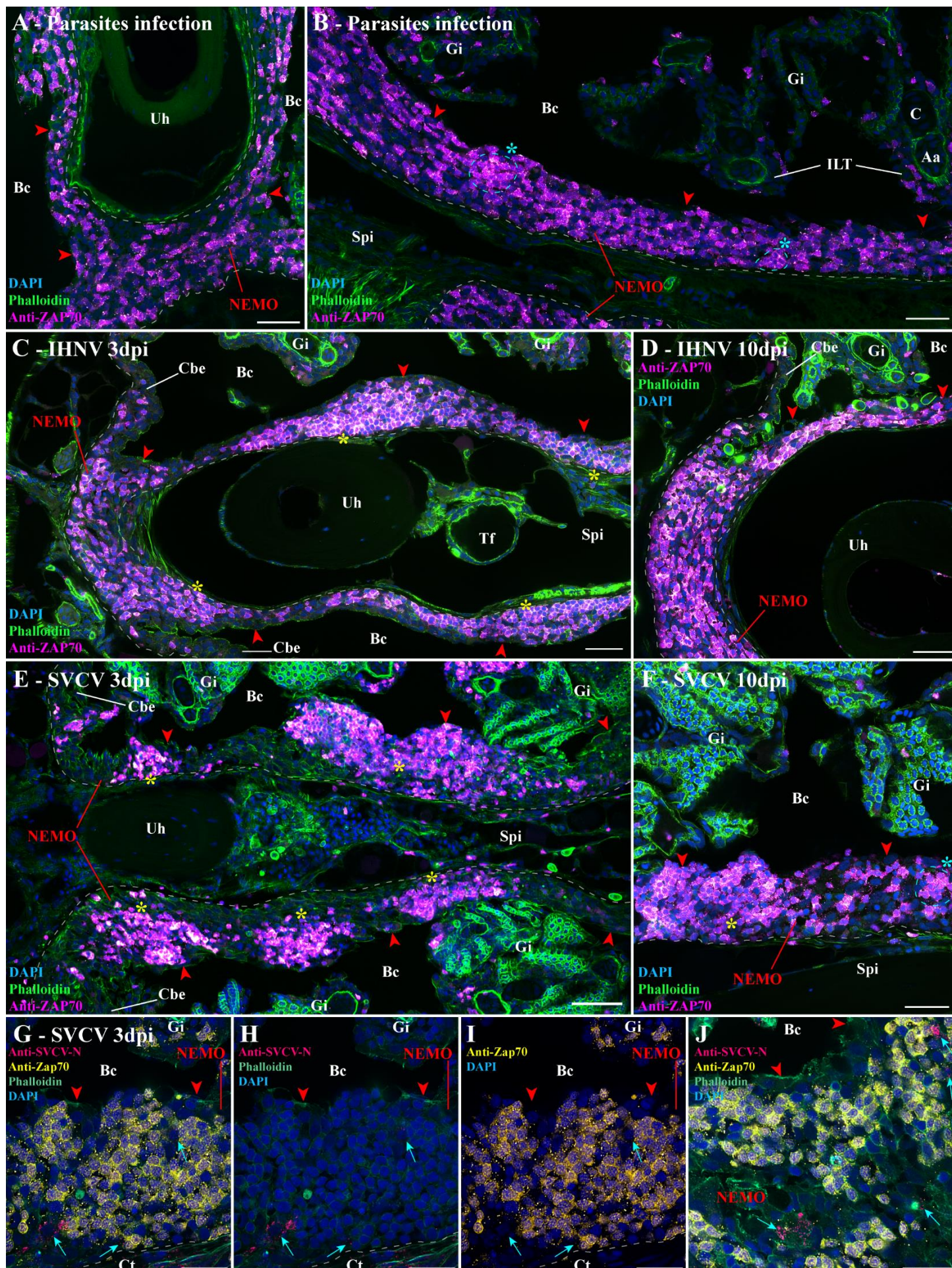
505 In agreement with our main hypothesis, these results provide a strong evidence for the
506 involvement of NEMO in immune responses to local infections as well as infections at distant
507 body sites. However, while our study provides a solid foundation to study NEMO's
508 involvement during infection, further research is required to strengthen our understanding of
509 NEMO's contribution to the teleost immune response.

510

511 **Figure 5 – Structural response of NEMO to viral and parasitic infections.** (A,B) Cryosections displaying NEMO
512 (red arrowheads) of adult zebrafish naturally co-infected with three parasites diseases (*Pseudoloma neurophilia*,
513 *Pseudocapillaria tomentosa*, and *Myxidium streisingeri*) labeled with anti-ZAP70 antibody (magenta hot). The
514 distribution of ZAP70-positive cells in NEMO appears more heterogeneous than in uninfected fish. In addition,
515 some the labeled cells formed small clusters (cyan stars). (C,D) Cryosections from adult zebrafish bath-infected
516 for 24h with IHNV. After more prominent aggregation of ZAP70-positive cells at 3 dpi (yellow stars) (C), the
517 distribution of T/NK cells reverted to a more homogeneous state by 10 dpi (D). (E,F) Cryosections from adult
518 zebrafish bath-infected for 24h with SVCV. NEMO displayed striking aggregation of T/NK cells into distinct
519 clusters at 3 dpi (yellow stars) (E). A week later, NEMO displayed both large (yellow star) and small clusters (cyan
520 star) of ZAP70-positive cells (F). (G-J) Cryosections from zebrafish three day after SVCV infection co-labeled
521 with anti-ZAP70 antibody (yellow) and anti-SVCV-N antibody (cherry) displaying cells loaded with virus material
522 (cyan arrows) neighboring large clusters of ZAP70-positive cells. Annotations: Aa, Afferent artery; Bc, Branchial
523 cavity; C, Cartilage; Cbe, Cavobranchial epithelium; Ct, Connective tissue; Dpi, day post-infection; Gi, Gills;
524 IHNV, Infectious hematopoietic necrosis virus; ILT, Interbranchial lymphoid tissue; Spi, Sub-pharyngeal isthmus;
525 SVCV, Spring viremia of carp virus; Tf, Thyroid follicle and Uh, Urohyal bone. Scale bars: 50 μm (E), 30 μm (A-
526 D,F), and 20 μm (G-J).

527

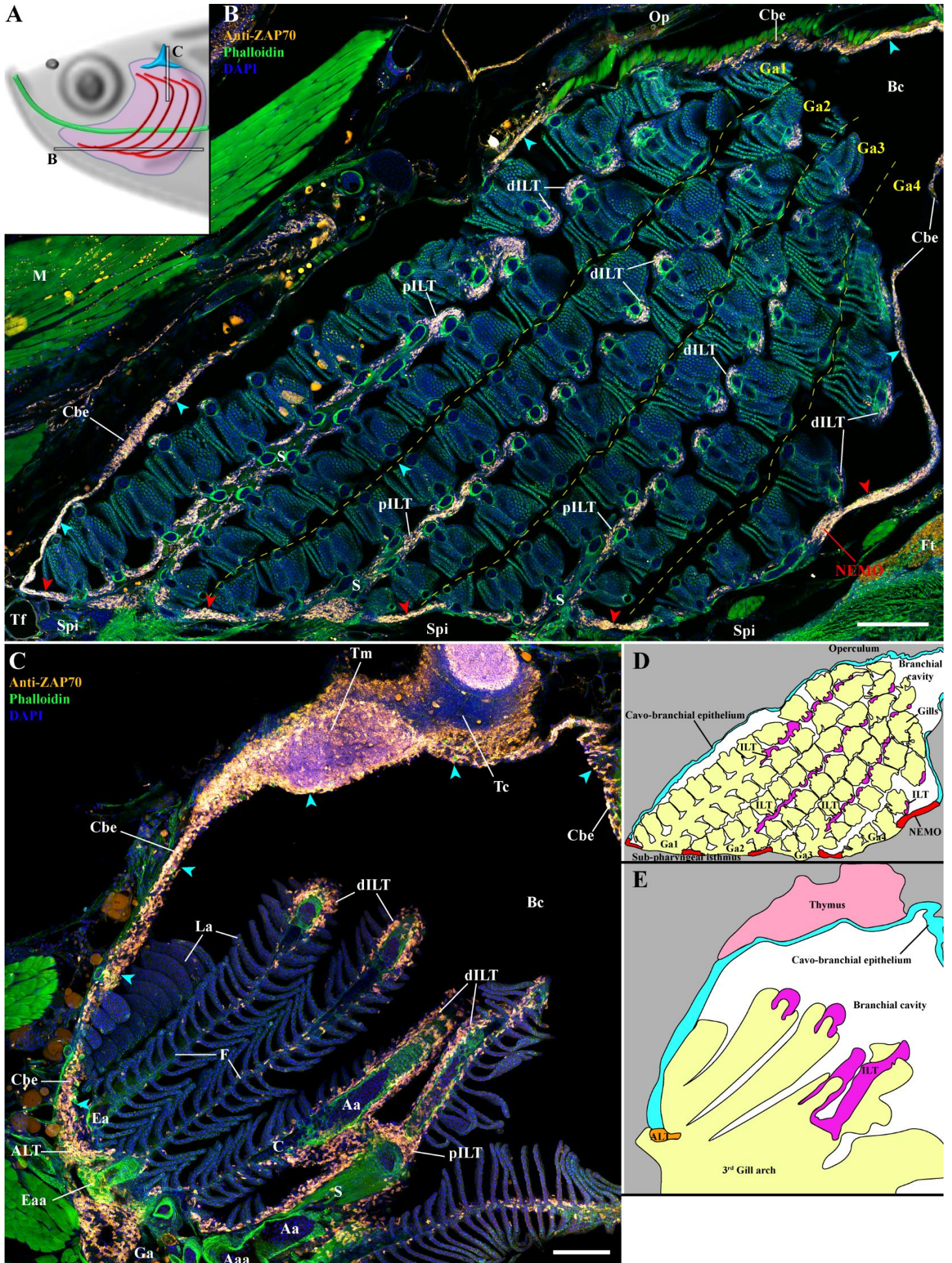
528



530 **NEMO, the ILTs, and ALTs as a cohesive unit of a vast lymphoid network inside the**
531 **branchial cavity.**

532 Our next objective was to further investigate NEMO in the context of the branchial cavity.
533 NEMO was intimately connected to the eight ILTs and sixteen ALTs (**Fig.1,S4**) in a way that
534 was very striking in the 3D reconstructions (**Video.S2**). Importantly, the analysis of the anti-
535 cytokeratin staining showed that NEMO and gill lymphoid aggregates share the same network
536 of reticulated epithelial cells (**Fig.S5 A** –red stars, **Video.S7**), indicating that NEMO, the ALTs,
537 and the ILTs a form cohesive unit within the branchial cavity (**Fig.1**). In order to better
538 appreciate the relation between NEMO and the lymphoid aggregates, we also looked at the
539 structural response of the ILTs to the different infections. In parasite-infected fish, both ILTs
540 and NEMO displayed a similar structural response as described above (**Fig.S9 A**). In both
541 SVCV-infected and IHNV infected-fish, however, the ILTs were strongly diminished while
542 NEMO persisted ((36) and **Fig.S9 B,C**) at 3 dpi, suggesting that NEMO and gills lymphoid
543 aggregates may play a different role in cellular responses to viral infections. While NEMO is
544 likely involved these responses based on its size, composition and location, further studies are
545 needed to understand its precise role, as well as its relationships with ILTs and ALTs.

546 In addition to the ILT and ALTs, NEMO was also in continuity with regions of the cavo-
547 branchial epithelium that also contained numerous T/NK cells (**Fig.1 B** – cyan arrowheads).
548 Using 3D multi-field of view imaging to investigate larger regions of the branchial cavity, we
549 found that much of the cavo-branchial epithelium (**Fig.6 B,C** – cyan arrowheads) displayed a
550 high concentration of ZAP70 positive cells, forming a vast lymphoid network within the
551 branchial cavity that links NEMO, the sixteen ALTs, the eight ILTs and the two thymus lobes.
552 Further analysis showed this lymphoid network extended beyond the branchial cavity region
553 (**Fig.S10**), reaching the skin via the operculum opening (not shown), as well as the pharyngeal
554 epithelium and the oesophagus epithelium (**Fig.S10 A**). This high T/NK cell concentration
555 continuity further extended along the anterior segment of the pharynx and the mouth (**Fig.S10**
556 **B,C**), from which it connected with the SALT via the non-keratinized sides of the mouth
557 opening (**Fig.S10 D**). In line with a previous study describing teleost fish SALT (34), it then
558 connected with the NALT via a skin network of T/NK cells located in the basal layers of the
559 epidermis and surrounding club cells (**Fig.S10 E-F and Video.S8**). Noteworthy, localized
560 clusters of ZAP70-positive cells were observed in the epidermis of the zebrafish head, which
561 may represent localized structured units of the SALT (**Fig.S10 C-D,F** – green stars).



563 **Figure 6 – NEMO as part of a larger lymphoid network.** (A) Scheme illustrating the localization the adult
564 zebrafish NEMO images acquired from 30 µm whole-head cryosections labeled with anti-ZAP70 antibody (orange
565 hot) to reveal T/NK cells (B-C). NEMO (red arrowheads) is part of lymphoid tissue continuity comprising a
566 ZAP70-positive cells-rich cavobranchial epithelium (cyan arrowheads) and which connects all the lymphoid
567 structures of the branchial cavity. (D) Scheme describing the different anatomic region displayed by the coronal
568 cryosection presented in (B). (E) Scheme describing the different anatomic regions displayed by the transversal
569 cryosection presented in (C). Annotations: Aa, Afferent artery; Aaa, Afferent arch artery; ALT, Amphibranchial
570 lymphoid tissue; Bc, Branchial cavity; C, Cartilage; Cbe, Cavobranchial epithelium; dILT, distal Interbranchial
571 lymphoid tissue; Ea, Efferent artery; Eaa, Efferent arch artery; Ft, Fat tissue; Ga, Gill arch; ILT, Interbranchial
572 lymphoid tissue; La, Lamellae; M, Muscles; Op, Operculum; pILT, proximal Interbranchial lymphoid tissue; S,
573 Septum; Spi, Sub-pharyngeal isthmus; Tc, Thymus cortex; Tf, Thyroid follicle and Tm, Thymus medulla. Scale
574 bars: 200 µm (A) and 100 µm (B).

575

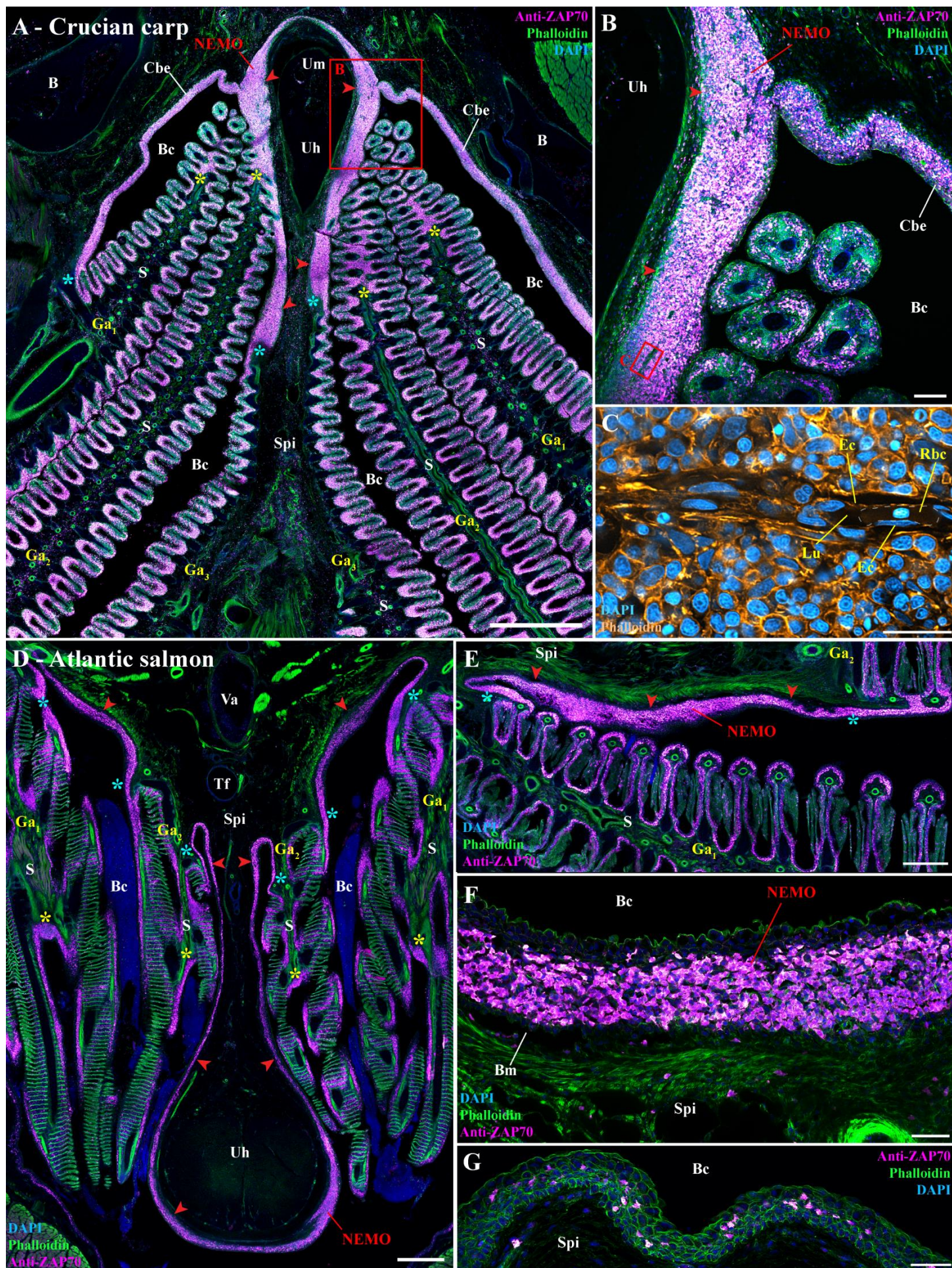
576 **NEMO and its cohesion with ILTs and ALTs in other teleost fish species.**

577 Our next objective was then to determine if NEMO and the lymphoid organization of the
578 branchial cavity we described exist in other fish species. Since the zebrafish is a small
579 representative of the cyprinid fish family, we first asked whether a larger cyprinid would share
580 the same branchial cavity lymphoid organization. For this, we labeled wild crucian carps
581 (*Carassius carassius*) with the anti-ZAP70 antibody, which revealed a lymphoid organization
582 that was strikingly similar to the zebrafish (**Fig.7 A-C**). Crucian carp NEMO formed an
583 important mass of T/NK cells wrapped around the urohyal bone that extended along the sub-
584 pharyngeal isthmus. Noteworthy, ZAP70-positive cells were also observed within the marrow
585 of the crucian carp urohyal bone. The close association of NEMO with the ILTs and the ALTs
586 was particularly striking, suggesting it likely remain unaffected by large body-size variations.
587 Finally, NEMO was also connected to the ZAP70-positive cells-rich mucosal epithelium lining
588 the branchial cavity (**Fig.7 A,B**). Intriguingly, whereas in the zebrafish NEMO was not
589 infiltrated by endothelial vessels, NEMO of crucian carp contained clear endothelial structures
590 in which red blood cells could be observed (**Fig.7 B,C**).

591 We then extended our investigation to the adult Atlantic salmon (*Salmo salar*), a representative
592 salmonid (**Fig.7 D-G**). While adult Atlantic salmon is anatomically divergent from zebrafish
593 and crucian carp (E.g. open branchiostegal rays), and displays different adaptations (E.g.
594 Atlantic salmon is an anadromous marine fish), we found a structure very similar to cyprinid
595 NEMO in that it is also wrapped around the urohyal bone and intimately connected to the gill
596 lymphoid aggregates (**Fig.7 D,E**). In contrast to the abundance of T/NK cells in Atlantic salmon
597 NEMO (**Fig.7 F**), fewer ZAP70-positive cells were observed in the mucosal epithelium anterior
598 to the urohyal bone (**Fig.7 G**). During our literature search, we came across one amazing old
599 research article from 1939 on the Atlantic salmon thyroid in which we could recognize a
600 structure that was highly reminiscent of NEMO (84). In that paper, the putative NEMO can be
601 observed at younger stages of Atlantic salmon development such as fry and parr. We could also
602 recognize a similar structure reminiscent of NEMO within the second figure of a study on the
603 thyroid of three-spined stickleback (*Gasterosteus aculeatus*), a representative of the
604 gasterosteid (85), a family belonging to the most derived clade of euteleost, the percomorphs.

605 Collectively, this probing comparative study indicates that NEMO and the branchial cavity
606 lymphoid organization we describe here in zebrafish are conserved among members of the
607 cyprinid and salmonid families, the two most extensively studied and farmed families
608 worldwide, as well as in some percomorphs. Moreover, our data suggest that cohesiveness with
609 gill lymphoid aggregates and the anatomical associations with the urohyal bone and sub-
610 pharyngeal isthmus might represent typical features of NEMO across different teleost species.

611



613 **Figure 7 – NEMO and its cohesion with ILTs and ALTs in other teleost fish species.** (A-B) Cryosections from
614 wild crucian carp labeled with anti-ZAP70 antibody (magenta hot). This larger representative of the cyprinids than
615 zebrafish also NEMO (red arrowheads), ILTs (yellow stars) and ALTs (cyan stars), which are all interconnected
616 by a clear lymphoid network. (C) Zoom from panel (B) in which phalloidin (orange hot) and DAPI (cyan hot)
617 staining revealed the presence of endothelial vessels containing red blood cells. Transversal (D) and coronal (E)
618 cryosections of an adult Atlantic salmon (1.5 kg) labeled with anti-ZAP70 (magenta hot) displaying NEMO (red
619 arrowheads), ILTs (yellow stars), ALTs (cyan stars). As for cyprinids, NEMO (red arrowheads) of this
620 representative of the salmonid family is located at the ventral convergence of gill arches, interconnected with gills
621 lymphoid aggregates, and closely associated with the urohyal bone. It is particularly enriched in ZAP70-positive
622 cells (F). In contrast, the mucosal epithelium lining the region directly anterior to the urohyal bone only displayed
623 scarce T/NK cell (G). Annotations: B, Bone; Bc, Branchial cavity; Bm, Basement membrane; Cbe, Cavobranchial
624 epithelium; Ec, Endothelial cell; Ga, Gill arch; Lu, Lumen; Rbc, Red blood cell; S, Septum; Spi, Sub-pharyngeal
625 isthmus; Tf, Thyroid follicle; Uh, Urohyal bone; Um, Urohyal marrow and Va, Ventral aorta. Scale bars: 1000 μ m
626 (A), 500 μ m (D), 400 μ m (E), 100 μ m (B), 50 μ m (F,G), and 20 μ m (C).

627

628 DISCUSSION

629 In the present study, we investigated the structural organization of lymphoid tissues in the
630 zebrafish branchial cavity. We show here that the tissues lining the branchial cavity, which are
631 highly exposed to the pathogens of the aquatic environment, present a complex network of
632 connected immune tissues. Advanced imaging of this region led us to identify a novel mucosal
633 lymphoid organ, which we tentatively named the Nemausean Lymphoid Organ (NEMO), that
634 is associated to the fish pharyngo-respiratory tract. Detailed investigations of its structural
635 organization by light- and electron-microscopy provided a solid foundation to characterize
636 NEMO as a lymphoid organ, such as the presence of an intricate network of reticulated
637 epithelial cells. Importantly, NEMO was a prominent constituent of a cohesive unit, formed
638 with ILTs and ALTs, of a lymphoid network interconnecting all the lymphoid structures in the
639 branchial cavity. This highlights a new level of integration of the surveillance and defense
640 system associated to the fish pharyngo-respiratory tract. Given the central localization of
641 NEMO within the branchial cavity, we hypothesized that NEMO could constitute a secondary
642 lymphoid organ in which immune responses would occur. This idea was supported by the
643 characterization of its immune cell populations that showed a high-enrichment in T/NK cells
644 and B cells mixed with antigen-presenting cells, and by the lack of expression of the
645 recombinase required for V(D)J rearrangements, RAG2. NEMO also contains ZAP70⁺ PCNA⁺
646 proliferating T cells, and ZAP70⁺ MHCII⁺ and ZAP70⁺ TNF α ⁺ activated T cells, further
647 strengthening the hypothesis that it is a secondary lymphoid organ. Following infection by
648 different pathogens, NEMO underwent structural changes involving the formation of ZAP70⁺
649 cells clusters, suggesting direct involvement in immune responses.

650 During our investigations, we could make an initial appreciation of NEMO's ontology using
651 our data and the zebrafish histology atlas (<https://bio-atlas.psu.edu/zf/progress.php>), and
652 discovered that NEMO appears surprisingly late during development. Whereas the main
653 lymphoid organs (thymus, spleen, kidney) are already present by the two first weeks of the
654 zebrafish development (86, 87), NEMO likely appears around the 4th-6th weeks of development,
655 right after the larval-juvenile transition stage. Thus, NEMO's development coincides with the
656 emergence of a fully mature adaptive immunity (87, 88). The gill lymphoid aggregates (ALT
657 and ILT), to which NEMO is tightly connected, also appear during the same time window, or
658 possibly just after the development of NEMO. The appearance of these lymphoid structures is
659 particularly striking when one considers that in 3 wpf zebrafish, besides for the thymus lobes,
660 the branchial cavity contains very few T/NK cells. Further work will be required to understand
661 the developmental mechanisms involved in this drastic transformation of the immune landscape
662 of the branchial cavity, and its impact on the fish susceptibility to infections. Interestingly, it

663 is well known that fish fry are highly sensitive to many viral and bacterial infections compared
664 to adults. In mammals, thyroid hormones have a significant impact on lymphoid organs'
665 development and biology (89, 90). For example, early removal of the thyroid in rats impairs
666 lymphoid organs morphology and functions (91). In zebrafish, thyroid hormones are important
667 for the larval-juvenile transition stage, and they also influence the size of the thymus (92–94).
668 The possibility that thyroid hormones may impact NEMO's development and, more generally
669 the relocation of the T-cells in the branchial cavity, would deserve some attention. The presence
670 of a recently reported zebrafish cell population sharing molecular markers with mammalian
671 lymphoid tissue inducer cells (LTi) (15), a type of innate lymphoid cell that is involved in the
672 formation of certain secondary lymphoid organs in mammals (95), should also be investigated
673 in NEMO and in the branchial cavity at the end of the larval-juvenile transition stage.

674 An interesting question is whether NEMO has counterparts among vertebrates or if this organ
675 represents an independent solution developed by certain fish species to combat infectious
676 diseases. The evolutionary history of lymphoid organs has been investigated and intensely
677 debated using various terminologies and classification criteria (3–7, 9, 10). In addition to the
678 thymus, the presence of lymphoid aggregates associated to the pharyngeal region has been
679 reported in mammals, birds, reptilians, and amphibians, but so far not in teleostean or
680 chondrosteian fish. Over a century ago, Salkind mentioned the existence of lymphoid
681 concentrations within the lower pharynx of Brook lamprey (*Lampetra planeri*), an agnathan;
682 he considered that these structures were distinct from the presumptive thymus (9). The absence
683 of prior recognition of a prominent pharyngeal lymphoid structure such as NEMO underscores
684 that teleost fish lymphoid organization remains imperfectly comprehended. Collectively, a
685 fascinating question that arises from this work is whether the formation of mucosal secondary
686 lymphoid structures within the pharyngo-respiratory region is a conserved developmental
687 program shared by vertebrates.

688 In mammals, the nasopharyngeal area is protected by a set of mucosal secondary lymphoid
689 organs called tonsils, which collectively form the Waldeyer's tonsillar ring (96). Several lines
690 of evidence support the hypothesis that NEMO may represent a fish analogue of mammalian
691 tonsils. NEMO, like the tonsils, is a mucosal lymphoid organ located within the pharyngo-
692 respiratory tract, which is exposed to the external environment. As tonsils, NEMO constitutes
693 a mass of lymphoid cells structured by an intricate network of reticulated epithelial cells.
694 Moreover, in certain fish species NEMO exhibits clear signs of vascularization. NEMO is part
695 of a larger lymphoid network containing 25 lymphoid structures (8 ILTs, 16 ALTs, and NEMO)
696 that are strategically positioned within the pharyngo-respiratory region at sites exposed to
697 antigens encountered during feeding and breathing. This arrangement might represent in fish a
698 distant functional analogue of the Waldeyer's ring of tonsils. Finally, as palatine tonsils, NEMO
699 appears relatively late in development at a site associated with the 2nd pharyngeal pouch (97–
700 100). However, mammalian tonsils display a more complex structural organization than
701 NEMO, such as well-defined T cell and B cell zones. Similarly, the presence of germinal-like
702 centers in NEMO remains to be explored.

703 The analysis of NEMO cellular composition is particularly significant for our understanding of
704 teleost fish immunology. We showed that NEMO contains more T/NK cells than the spleen,
705 which is considered as the primordial secondary lymphoid organ in fish (4), suggesting it may
706 play an essential role for the homeostasis of adaptive immunity. Ablation of NEMO or T-cell
707 depletion experiments, for example using rag2 mutant zebrafish (101), could provide valuable
708 information on NEMO's function. In addition, we showed that NEMO also possess a significant
709 plasma/B cells population. Secretory antibodies plays an important role in the maintenance of
710 the branchial cavity homeostasis, as shown by Xu *et al* (102), the experimental depletion of
711 secretory IgT immunoglobulin in rainbow trout induced gill dysbiosis, inflammation and tissue

712 damages. Further studies would have to clarify the role of NEMO in immune system regulation
713 and the screening of external pathogens from local microbiota.

714 The infection experiments we performed have been key to propose NEMO as a secondary
715 lymphoid organ. After 3 day of infection by SVCV, NEMO displayed a rearrangement of T/NK
716 cells into large clusters surrounded by cells carrying virus material. Further studies would have
717 to determine the nature of these concentrations of lymphoid cells we observed in NEMO and if
718 they represent structures favoring processes of adaptive immunity such as antigen-presentation.
719 It would be particularly interesting to determine if they are associated to the formation of
720 melanomacrophage center (MMC), which are immune structure that have been suggested as
721 potential fish analogue of mammalian germinal center (103).

722 Our observations revealed a structural cohesion between NEMO, ALT, and ILTs, all sharing
723 the same network of reticulated epithelial cells. The ILT was the first structured mucosal
724 lymphoid tissue discovered in fish. Studies in salmonids showed that it may represent a non-
725 conventional secondary lymphoid tissue (26, 73, 104, 105). This was followed by our
726 description of the ALT in zebrafish. Consistent with studies in salmon, the zebrafish ILT and
727 ALT displayed features of secondary lymphoid organ. In this study we showed that ILTs and
728 ALTs are not just a set of 24 distinct lymphoid structures, they are bound together by a more
729 prominent lymphoid organ that also possess features of secondary lymphoid organs, NEMO.
730 Intriguingly, NEMO, the ALTs and ILTs did not display a similar structural response to IHNV
731 and SVCV infections in adult zebrafish (36). The zebrafish ILT and ALT are first strongly
732 reduced by 3 dpi, which is consistent with a reduction of the ILT described in Atlantic salmon
733 infected with infectious salmon anemia virus (73), whereas NEMO persisted. This constitutes
734 a major difference between NEMO and the gill lymphoid aggregates, which indicate they likely
735 bear different immune functions. However, NEMO and the ILT displayed a similar
736 rearrangement of ZAP70 cells in the fish naturally co-infected with multiple parasites. Further
737 studies would have to determine if the gill lymphoid aggregates are constituents of NEMO.

738 Our investigations of the whole branchial cavity revealed the presence of a vast lymphoid
739 network that links NEMO, ILTs, ALTs and thymus lobes altogether into a sophisticated super-
740 structure of the fish immune system, which suggest the branchial cavity may act as a lymphoid
741 nexus. The implications of this lymphoid super-structure for the homeostasis of the fish immune
742 system and its interactions with other tissues/organ remains to be deciphered.

743 In this study, we recognized NEMO in representatives of distant teleost fish species families:
744 two cyprinids, one salmonid, and a Percomorph. This observation suggests that NEMO is likely
745 present in most fish families. We anticipate a significant level of structural variability in NEMO
746 across teleost fish species, given the taxonomic and morphologic diversity within this group.
747 However, our data suggest that its position around the urohyal bone and at the convergence of
748 gill arches along the sub-pharyngeal isthmus are conserved features. Importantly, as in
749 zebrafish, the integral unit formed by NEMO and the gill lymphoid aggregates was clear in all
750 the analyzed fish species, suggesting that the NEMO/ALT/ILT apparent unity might be an
751 essential arrangement for immune responses in the branchial cavity. Taking into account our
752 previous comparative studies, ILTs seems only present within the gills of “basal” teleost,
753 whereas ALT and NEMO could be observed in all the analyzed teleost fish species so far. It
754 would be of particular interest to investigate if the morphology of the branchial cavity, and more
755 specifically the evolution of the branchiostegal rays (49), influence the existence or the
756 morphology of NEMO and its unity with gill lymphoid aggregates.

757

758

759 CONCLUSION

760 Altogether, our study provides new insights about the teleost fish immune system and its
761 structural organization. We identified a novel lymphoid organ within the pharyngo-respiratory
762 region of adult zebrafish and other teleost species, which we named “Nemausean Lymphoid
763 Organ (NEMO)”. Our investigations led to the idea that NEMO is a fish mucosal secondary
764 lymphoid organ that shows features of mammalian tonsils. Intimately associated with gill
765 lymphoid aggregates, NEMO appears as a potential key lymphoid hub coordinating lymphocyte
766 traffic and defense mechanisms within the fish respiratory mucosa. Collectively, our findings
767 contribute to a better understanding of the evolution of the vertebrate immune system, and
768 provide new insights in fish immunology. Gill immunity is of growing importance both for
769 future vaccines in aquaculture and for the development of disease models in zebrafish.

770

771

772 MATERIALS AND METHODS

773 *Animal Care and Ethic Statement*

774 Experiments were conducted in compliance with the animal care guidelines, ethical standards
775 and legislation of the European Union, France and Norway, and in consultation with local ethics
776 committees. Animal experiments performed in the present study were carried out at the IERP
777 fish facilities (building agreement n°C78-720, doi.org/10.15454/1.5572427140471238E12) of
778 the INRAE Research Center at Jouy-en-Josas, France, in compliance with the recommendations
779 of Directive 2010-63-EU on the protection of animals used for scientific purposes. These
780 infection protocols were authorized by the institutional review ethics committee, COMETHEA,
781 of the INRAE Research Center. Authorizations were approved by the French Ministry of
782 Agriculture (authorization number APAFIS# 22150-2019062811528052).

783 Animal experimentations, handling, and euthanasia were performed by well-trained and
784 authorized staff. Specimen were euthanized using an anesthetic overdose of buffered tricaine.

785 The experiments were performed using AB wild-type zebrafish (around 1 year, unless
786 specified) (N=36) and the following transgenic lines: *Tg(lck:EGFP)* (N=3) (16),
787 *Tg(fli1a:EGFP)^{y1}* (N=3) (57), *Tg(mpx:GFP)ⁱ¹¹⁴* (N=3) (63), *Tg(mhc2dab:GFP)^{sd6}* (N=3) (64),
788 *Tg(mfap4:mCherry-F)^{ump6}* (N=6) (65), *Tg(Cau.Ighv-ighm:EGFP)^{sd19}* (N=3) (71),
789 *Tg(rag2:DsRED)* (N=3) (72), *Tg(cd41:GFP)* (N=3) (74), and *Tg(tnfa:eGFP-F)^{ump5}* (N=3) (78).

790 The study includes three laboratory grown adult zebrafish (1 year) naturally co-infected with
791 *Pseudoloma neurophilia*, *Pseudocapillaria tomentosa*, and *Myxidium streisingeri*, provided by
792 the Oehlers' laboratory (SINGAPORE). The fishes were held at the IMCB Zebrafish facility
793 under IACUC approval 211667, and were sampled as part of a culling following veterinarian
794 diagnosis. Animal handling and euthanasia were performed in accordance with Singaporean
795 regulations.

796 Two healthy adult Atlantic salmon (weight: 1500g), laboratory-raised by NIVA (Solbergstrand-
797 NORWAY), were provided by PHARMAQ, a division of Zoetis. The fish were handled and
798 euthanized in strict accordance with Norwegian legislation by authorized staff.

799 Three wild crucian carps (40g: both sex), captured using nylon net in October 2020 in Tjernsrud
800 pond (Oslo-NORWAY), with a healthy appearance upon sampling were provided by the

801 Lefevre-Nilsson group from the University of Oslo. Specimen were sampled and euthanized in
802 compliance with Norwegian animal welfare laws (Dyrevelferdsloven), carried out as part of the
803 authorized project FOTS permit ID 16063, and following the instruction about use of animal
804 for research (Forskriften om bruk av dyr I forsøk).

805

806 *Infection experiments with SVCV and IHNV*

807 Spring Viremia of Carp Virus (SVCV) and Infectious Hematopoietic Necrosis Virus (IHNV)
808 infectious challenges were carried out on wild-type zebrafish of the AB strain, aged 16 months
809 and weighing 0.8g (+/-0.03g). Fish were acclimatized for 48h at 22°C (pH 7, conductivity
810 200µS/cm²) in 1.5L aquaria. Two groups of eight fish each were then infected by immersion
811 for 48 h using the reference SVCV strain VR-1390 (PMID: 29114248) and the IHNV strain 25-
812 70 adapted to 25°C (108) and the IHNV strain 25-70 adapted to 25°C (109), at a final
813 concentration of 104 PFU/ml. The water flow was stopped for 48 h, followed by daily water
814 change. Fish were euthanized and sampled at 3 and 10 days post infection by IHNV, and at 3
815 and 10 dpi by SVCV. Non-infected controls were prepared in parallel (n = 4).

816

817 *Electron microscopy*

818 Juvenile zebrafish (9 wpf, N=3) were euthanized and immediately immersed in 20mL of
819 fixative (4% Formaldehyde, 0.8% Glutaraldehyde GA, in 1X PHEM buffer (110, 111) pH7.2
820 in fish water) for 24h at room temperature (RT), followed by a 24h incubation at 4°C. Samples
821 were quenched in 100 mM glycine for 2h at RT and rinsed with 100 mM sodium bicarbonate
822 buffer (pH 6.5). For postfixation, samples were incubated on ice with a solution of 2% osmium
823 tetroxide and 1.5% potassium ferricyanide in 100 mM sodium bicarbonate buffer (112), rinsed
824 5 times with 100mM sodium bicarbonate buffer and 2 times with 50 mM maleate buffer (pH
825 5.15), and incubated in 2% uranyl acetate in 50 mM maleate buffer for 3h (113). Following
826 washes in 50 mM maleate buffer, gradual dehydration was achieved by “progressive lowering
827 of temperature” (114) using the following sequential incubations: 1h 30% ethanol on ice, 1h
828 50% ethanol on ice, 30min 1% uranyl acetate in 70% ethanol at -20°C, 1h 70% ethanol at -
829 20°C, 90min 80% ethanol at -30°C, 90min 90% ethanol at -30°C, 2h 96% ethanol at -30°C, 16h
830 100% ethanol at -30°C, 3 times 2h 100% dry ethanol (3Å molecular sieve (115)) at -30°C, 2
831 times 30min dry acetone at -30°C, and 14h 25% EPON in dry acetone at RT. EPON (116) was
832 prepared with a ratio of 3:7 (DDSA:NMA) containing 1% DMP-30. Specimen infiltration was
833 done by a 24h incubation in 100% EPON at RT. Samples were then embedded in fresh EPON
834 using flat embedding molds and oriented after 3h of polymerization at 60°C. Finally,
835 polymerization was performed for 48h at 60°C followed by a 24h curing period at RT. Targeted
836 trimming was aided by staining semithin (300 nm) sections with 0,1% toluidine blue in borate
837 buffer (pH 11) at 80°C (117, 118) to facilitate the orientation in the sample. Samples were
838 sectioned at 60 nm thickness on a Leica UCT ultramicrotome using Diatome 45° ultra knives
839 and mounted on carbon coated, formvar film on 2 mm single hole copper grids. Sections were
840 then stained with 4% uranyl acetate in 50% methanol for 1h (119), followed by a 20 seconds
841 incubation with Reynolds lead citrate (120). Images were acquired at 120 kV with a Jeol JEM-
842 1400 electron microscope using a Tvips 216 camera. The manually recorded images were
843 aligned using the plugin big stitcher in ImageJ, montaged using gimp for layer projection, and

844 colored using photoshop CS6. If applicable, generation of a tile pyramid and visualization via
845 java was done using Open-Seadragon and Openlayers on a basic html site.

846 Several ultrastructure maps of NEMO are available at the following internet addresses:
847 (https://wohlmann.github.io/2019019_004_M1c/) (https://wohlmann.github.io/2019019_004_N2/)

848

849 ***3D reconstruction of the zebrafish NEMO***

850 Following euthanasia, adult zebrafish heads (15 wpf, N=3) were fixed in a solution of 4%
851 methanol-free formaldehyde (Thermofisher) in 60 mM HEPES buffer (pH 7.4) for 24 h at room
852 temperature, followed by a 3 days incubation at 4°C. For decalcification, samples were
853 incubated in a solution of 13% EDTA (pH 7.8), 0,1% tween (Sigma Aldrich) and 1% triton X-
854 100 (Sigma Aldrich), in ddH₂O for 5 days at RT under gentle rocking. Samples were then
855 saturated for 24h at RT in a blockaid solution (Thermofisher) with 0,5% triton X-100 and 0,1%
856 tween. T/NK lymphocyte were labeled using a rabbit anti-ZAP70 monoclonal antibody (99F2
857 – Cell Signaling) diluted at 1:600 in Pierce™ Immunostain Enhancer solution (Thermofisher)
858 complemented with 0,5% triton X-100 and 0,1% Tween for 5 days at RT under gentle rocking.
859 Samples were then washed several times at RT in 1X PHEM buffer (60 mM PIPES, 25 mM
860 HEPES, 10 mM EGTA and 2 mM MgCl₂ in ddH₂O – pH 7.4 (110, 111)) with 0,5% triton X-
861 100 and 0,1% Tween (PHEM_{t-tw}), and incubated with goat anti-rabbit-Alexa647 (Jackson
862 ImmunoResearch) diluted at 1:400 in 1X PHEM_{t-tw}, complemented with phalloidin-TRITC
863 (Sigma Aldrich) at 3U/mL and DAPI (Thermofisher) at 5 µg/mL, for 5 days at RT under gentle
864 rocking. Samples were then first rinsed with 1X PHEM_{t-tw} and then 1X PHEM. Samples were
865 stored at 4°C in 1X PHEM until further processing. One sample was then sliced and mounted
866 onto a coverslip with slowfade glass mounting medium (Thermofisher) to control the quality
867 of the labeling and for wholemout imaging of the skin covering the head.

868 Tomography was performed using an automatized Zeiss LSM880 confocal microscope coupled
869 with a vibratome (Microm HM 650V from Thermo Scientific). For sectioning, ZAP70-labeled
870 zebrafish heads were embedded in 6% agarose in water into a 1 cm square plastic chamber and
871 orientated for appropriate cross-sectioning with rostral side on top. Once set, agarose box was
872 resized using a razor blade and was attached with superglue on a metal surface with rostral side
873 orientated on top and placed into a tank filled with water. The following automated process was
874 then applied: a 80 µm thick layer was removed from the surface of the block containing the
875 samples by the vibratome, followed by the immediate imaging of the newly exposed surface
876 with the Zeiss LSM 880 microscope. Image were acquired in confocal mode, with a 20x Plan
877 Apo 1.0 NA water immersion objective, the wavelength 633 nm for excitation and 660-711 nm
878 band for emission and the wavelength 561 nm (Argon Laser) and 561-630 nm band (GaAsP
879 detector), sequential mode, mosaic of 12 x 12 fields, stack of 102 µm total volume and 6 µm
880 steps. Imaging steps were repeated The 3D files generated from acquisitions were processed
881 using Image J for alignment, stitching, and cropping. NEMO, the thymus lobes, the ALT, and
882 the ventral end of the gill arches, were manually segmented on each single layer based on the
883 phalloidin and anti-ZAP70 signals using Imaris in order to assemble the different 3-D
884 reconstructions. IMARIS was also used to generate the 3D videos.

885 ***Immunofluorescence - Cryosections***

886 Following euthanasia, whole adult zebrafish and dissected lower pharyngeal areas of both
887 Atlantic salmon and crucian carp, were fixed in a solution of 4% methanol-free formaldehyde
888 (ThermoFisher) in 60 mM HEPES buffer (pH 7.4) for 24 h at room temperature, followed by a
889 3 days incubation at 4°C. Atlantic Salmon and crucian carp samples were decalcified with a 5
890 days incubation in a solution of 13% EDTA (pH 7.8) in ddH₂O at RT under gentle rocking.

891 Samples were cryoprotected by two incubations in a solution of sucrose at 32% in ddH₂O, until
892 the specimens sunk to the bottom of the recipient, and embedded in Tissue-Tek O.C.T.
893 Compound (Sakura Finetek USA, Mountain View, CA, USA). Samples were flash-frozen in
894 isopentane, and sectioned using a CM1950 cryostat (Leica, Wetzlar, Germany). The resulting
895 30 µm cryosections were collected on Superfrost Plus slides (ThermoFischer) and stored at -
896 20°C. Samples used for stereology analyses were sectioned and recovered in standardized
897 uniform random way.

898 Following the protocols detailed in (36), immunofluorescence as follow. Briefly, following
899 saturation in blockaid solution (ThermoFisher), slides were incubated with one or several of the
900 following primary antibody / lectin: 1:300 rabbit anti-ZAP70 monoclonal antibody (99F2 – Cell
901 Signaling), 1:40 cytokeratin Pan Type I/II mouse monoclonal antibody cocktail (ThermoFisher),
902 1:300 mouse anti-PCNA monoclonal antibody (PC10 – ThermoFisher), 1:200 mouse anti-BTK
903 monoclonal antibody (D6T2C – Cell Signaling), and 1:20 mouse anti-SVCV-N monoclonal
904 antibody (BIO 331 – Bio-X Diagnostics). 1:200 peanut agglutinin lectin coupled with alexa594
905 (ThermoFisher). When necessary, sections were incubated with one or several of the following
906 cross-adsorbed secondary antibodies at 1:250: Goat anti-rabbit-Alexa647 (Jackson
907 ImmunoResearch), Goat anti-mouse-Alexa647 (Jackson ImmunoResearch), and Goat anti-
908 mouse-Alexa594 (Jackson ImmunoResearch). Where relevant, secondary antibodies or lectin
909 were co-incubated with fluorescent phalloidin (TRITC or FITC labeled – Sigma Aldrich) at
910 3U/mL, and DAPI (ThermoFisher) at 5 µg/mL. Slides were mounted with coverslips using
911 prolong-glass mounting medium (ThermoFisher).

912

913 ***Imaging and Image analysis***

914 3D images were acquired with the Zyla camera of a dragonfly 500 spinning disk confocal
915 microscope (Andor, Belfast, UK), with 40 µm pinholes and either a 20×/0.75-dry objective or
916 a 60×/1.4-oil-immersion objective. Acquisitions, stitches and deconvolutions (14-16 iterations)
917 were performed using in-build features of the Fusion software. Image analysis were carried out
918 using IMARIS and ImageJ/FIJI softwares. The acquisition and analyses of images were made
919 at the NorMIC imaging platform (University of Oslo, NORWAY).

920 The average volume of a zebrafish T/NK cell was quantified using IMARIS by reconstructing
921 the 3D structure of 15 random ZAP70-positive cells from 3D images of NEMO cryosections
922 coming from 3 different fish.

923 The volume of NEMO, and spleen, occupied by ZAP70-positive cells was calculated with
924 “point counting stereology” (121) using ImageJ to generate randomly placed 500 µm² and 100
925 µm² grids on single optical section images of the anterior segment of NEMO collected from 3
926 different fish. The amount of T/NK cells was then calculated by multiplying the total volume
927 of the organ by the fraction of the volume occupied by ZAP70-positive cells, which was then
928 divided by the average volume of a single T/NK cell.

929 Cell counting was performed manually using the “Cell counter” plugin on ImageJ on single
930 optical section images of the anterior segment of NEMO coming from 3 different fish. Graph
931 were generated using the software GraphPad Prism 7.

932

933 **ACKNOWLEDGEMENT**

934 We thank the Oslo NorMIC imaging platform (O. Bakke, F. Skjeldal and L. Haugen), the IBV
935 Electron-Microscopy facility (N. Roos), the histology platform of the FYSCCELL section (T.
936 Klungervik), the NCMZ zebrafish facility (C. Esguerra, AC. Tavera), the A*STAR IMCB
937 Zebrafish Facility, as well as K.Zulkefli and the Ella Maru studio (E. Marushchenko and K.
938 Zvorykina) for the scientific illustrations. We would also like to acknowledge the imaging
939 facility BioCampus Montpellier Ressources Imagerie (MRI) (M. Dejean and M. Lartaud),
940 member of the national infrastructure France-BioImaging supported by the French National
941 Research Agency (ANR-10-INSB-04, "Investments for the future"). We also address a special
942 thanks to C. Wiik-Nielsen and H. Hardersen at PHARMAQ, part of Zoetis, for providing us
943 with salmon samples, and to L. Gerber, G. Nilsson, and S. Lefevre (University of Oslo) for
944 providing crucian carp samples. We would also like to acknowledge A. Zapata, L. Du Pasquier,
945 A. Dalum, S. Khan, A. Kraus, M. Groß, E. Davydova, B. Mathiesen, A.López-Porras, JP.
946 Levraud, G. Lieschke, H. Winther-Larsen, N. Steinel, P. Elk, R. Hodge and E. Teyssier for their
947 highly appreciated help, discussion, and support. Finally, we thank all the persons that have
948 been involved in the creation of the different genetically modified zebrafish strains.

949 We thank the Norwegian Research Council for funding (No 144642 and No 329478). In
950 addition, PB and BV were supported by the Agence Nationale de la Recherche (France) (project
951 ANR-21-CE35-0019), and by the ERANET project Nucnanofish. MN-C was supported by the
952 french Agence Nationale de la Recherche [ANR-19-CE15-0005-01, MacrophageDynamics].

953

954 **AUTHOR CONTRIBUTIONS**

955 Conceptualization: PB, GG, and JR. Investigation: MN-C, JW, DR, and JR. Methodology: MN-
956 C, JW, DR, GG, and JR. Validation: JR. Writing - Original draft: GG, PB, and JR. Writing -
957 Review & Editing: MN-C, JW, DR, SO, FJ, SQ, BV, GW, IS, EK, PB, GG, and JR.
958 Visualization: JW and JR. Supervision: MN-C, IS, PB, BV, FJ, SQ, GG, and JR. Project
959 administration: JR. All authors contributed to the article and approved the submitted version.

960

961 **CONFLICT OF INTEREST**

962 The authors declare that the research was conducted in the absence of any commercial or
963 financial relationships that could be construed as a potential conflict of interest.

964

965

966

967

968 **ABBREVIATIONS**

969 Aa, Afferent artery; Aaa, Afferent arch artery; ALT, Amphibranchial Lymphoid Tissue; B,
970 Bone; Bc, Branchial cavity; Bm, Basement membrane; BTK, Bruton Tyrosine Kinase; Bv,
971 Blood vessel; C, Cartilage; Cbe, Cavo-branchial epithelium; Ct, Connective tissue; Cvs, Central
972 venous sinus; d-ILT, distal Interbranchial Lymphoid Tissue; Dpi, Day post-infection; Ea,
973 Efferent artery; Eaa, Efferent arch artery; Eav, Endothelial anastomotic vessels; Ec, Endothelial
974 cell; EM, Electron Microscopy; Ft, Fat tissue; Ga, Gill arch; GALT, Gut-Associated Lymphoid
975 Tissue; Gi, Gills; GIALT, Gill-Associated Lymphoid Tissue; H&E, Hematoxylin and Eosin;
976 HK, Head-Kidney; ILT, Interbranchial Lymphoid Tissue; IHNV, Infectious Hematopoietic
977 Necrosis Virus; La, Lamellae; Lu, Lumen; M, Muscles; MALT, Mucosa-Associated Lymphoid
978 Tissue; NALT, Nasal-Associated Lymphoid Tissue; NEMO, Nemausean lymphoid Organ; NK
979 cell, Natural Killer cell; Op, Operculum; PCNA, Proliferating Cell Nuclear Antigen; p-ILT,
980 proximal Interbranchial Lymphoid Tissue; Rbc, Red blood cell; S, Septum; SALT, Skin-
981 Associated Lymphoid Tissue; Sk, Skin; Spi, Sub-pharyngeal isthmus; SVCV, Spring Viremia
982 of Carp Virus; Tc, Thymus cortex; Td, tendon; TEM, Transmission Electron Microscopy; Tf,
983 Thyroid follicle; Tm, Thymus medulla; Tu, Tubule; Uh, Urohyal bone; Um, Urohyal marrow;
984 Va, Ventral aorta; Wpf, week post-fertilization; ZAP70, Zeta-chain-Associated Protein kinase
985 70.

986

987

988 **REFERENCES**

- 989 1. E. M. Akirav, N. Alonso-Gonzalez, L. A. Truman, N. H. Ruddle, "Lymphoid Tissues and Organs"
990 in *Fundamental immunology 7th edition (Willial Paul)* (2013), pp. 47–66.
- 991 2. J. Hofmann, M. Greter, L. Du Pasquier, B. Becher, B-cells need a proper house, whereas T-cells
992 are happy in a cave: the dependence of lymphocytes on secondary lymphoid tissues during
993 evolution. *Trends Immunol.* **31**, 144–153 (2010).
- 994 3. M. F. Flajnik, A cold-blooded view of adaptive immunity. *Nat. Rev. Immunol.* **18**, 438 (2018).
- 995 4. H. R. Neely, M. F. Flajnik, Emergence and Evolution of Secondary Lymphoid Organs. *Annu. Rev.*
996 *Cell Dev. Biol.* **32**, 693 (2016).
- 997 5. T. Boehm, I. Hess, J. B. Swann, Evolution of lymphoid tissues. *Trends Immunol.* **33**, 315–321
998 (2012).
- 999 6. A. Zapata, C. T. Amemiya, Phylogeny of Lower Vertebrates and Their Immunological
1000 Structures. *Curr. Top. Microbiol. Immunol.* **248**, 67–107 (2000).
- 1001 7. R. A. Good, The Development of Immunological Capacity in Phylogenetic Perspective. *Arch.*
1002 *Pediatr. Adolesc. Med.* **114**, 477 (1967).
- 1003 8. A. G. Zapata, Lympho-Hematopoietic Microenvironments and Fish Immune System. *Biology*
1004 *(Basel)*. **11**, 747 (2022).
- 1005 9. J. Salkind, Contributions histologiques à la biologie comparée du thymus. *Arch. Zool.*
1006 *expérimentale générale*. **55**, 81–322 (1915).
- 1007 10. A. Drzewina, Contribution à l'étude du tissu lymphoïde des Ichthyopsides. *Arch. Zool.*
1008 *expérimentale générale*. **4**, 145–338 (1905).

- 1009 11. N. S. Trede, D. M. Langenau, D. Traver, A. T. Look, L. I. Zon, The use of zebrafish to understand
1010 immunity. *Immunity*. **20**, 367–79 (2004).
- 1011 12. S. A. Renshaw, N. S. Trede, A model 450 million years in the making: zebrafish and vertebrate
1012 immunity. *Dis. Model. Mech.* **5**, 38–47 (2012).
- 1013 13. S. J. Carmona, S. A. Teichmann, L. Ferreira, I. C. MacAulay, M. J. T. Stubbington, A. Cvejic, D.
1014 Gfeller, Single-cell transcriptome analysis of fish immune cells provides insight into the
1015 evolution of vertebrate immune cell types. *Genome Res.* **27**, 451–461 (2017).
- 1016 14. G. J. Lieschke, A. C. Oates, M. O. Crowhurst, A. C. Ward, J. E. Layton, Morphologic and
1017 functional characterization of granulocytes and macrophages in embryonic and adult
1018 zebrafish. *Blood*. **98**, 3087–3096 (2001).
- 1019 15. P. P. Hernández, P. M. Strzelecka, E. I. Athanasiadis, D. Hall, A. F. Robalo, C. M. Collins, P.
1020 Boudinot, J.-P. Levrud, A. Cvejic, Single-cell transcriptional analysis reveals ILC-like cells in
1021 zebrafish. *Sci. Immunol.* **3**, eaau5265 (2018).
- 1022 16. D. M. Langenau, A. A. Ferrando, D. Traver, J. L. Kutok, J. P. D. Hezel, J. P. Kanki, L. I. Zon, A.
1023 Thomas Look, N. S. Trede, In vivo tracking of T cell development, ablation, and engraftment in
1024 transgenic zebrafish. *Proc. Natl. Acad. Sci. U. S. A.* **101**, 7369–7374 (2004).
- 1025 17. D. M. Page, V. Wittamer, J. Y. Bertrand, K. L. Lewis, D. N. Pratt, N. Delgado, S. E. Schale, C.
1026 McGue, B. H. Jacobsen, A. Doty, Y. Pao, H. Yang, N. C. Chi, B. G. Magor, D. Traver, An
1027 evolutionarily conserved program of B-cell development and activation in zebrafish. *Blood*.
1028 **122**, e1–e11 (2013).
- 1029 18. I. Salinas, Y.-A. Zhang, J. O. Sunyer, Mucosal immunoglobulins and B cells of teleost fish. *Dev.*
1030 *Comp. Immunol.* **35**, 1346–65 (2011).
- 1031 19. N. Danilova, J. Bussmann, K. Jekosch, L. A. Steiner, The immunoglobulin heavy-chain locus in
1032 zebrafish: identification and expression of a previously unknown isotype, immunoglobulin Z.
1033 *Nat. Immunol.* **6**, 295–302 (2005).
- 1034 20. V. Wittamer, J. Y. Bertrand, P. W. Gutschow, D. Traver, Characterization of the mononuclear
1035 phagocyte system in zebrafish. *Blood*. **117**, 7126–35 (2011).
- 1036 21. G. Lugo-Villarino, K. M. Balla, D. L. Stachura, K. Bañuelos, M. B. F. Werneck, D. Traver,
1037 Identification of dendritic antigen-presenting cells in the zebrafish. *Proc. Natl. Acad. Sci. U. S.*
1038 *A.* **107**, 15850–5 (2010).
- 1039 22. M. van der Vaart, H. P. Spaink, A. H. Meijer, Pathogen recognition and activation of the innate
1040 immune response in zebrafish. *Adv. Hematol.* **2012**, 159807 (2012).
- 1041 23. K. Sugimoto, S. P. Hui, D. Z. Sheng, M. Nakayama, K. Kikuchi, Zebrafish FOXP3 is required for
1042 the maintenance of immune tolerance. *Dev. Comp. Immunol.* **73**, 156–162 (2017).
- 1043 24. F. Barraza, R. Montero, V. Wong-Benito, H. Valenzuela, C. Godoy-Guzmán, F. Guzmán, B.
1044 Köllner, T. Wang, C. J. Secombes, K. Maisey, M. Imarai, Revisiting the teleost thymus: Current
1045 knowledge and future perspectives. *Biology (Basel)*. **10** (2021), doi:10.3390/biology10010008.
- 1046 25. A. Zapata, Ultrastructural study of the teleost fish kidney. *Dev. Comp. Immunol.* **3** (1979),
1047 doi:10.1016/S0145-305X(79)80006-3.
- 1048 26. B. H, K. EO, Anatomy of teleost fish immune structures and organs. *Immunogenetics*. **73**, 53–
1049 63 (2021).
- 1050 27. R. Simón, A. Martín-Martín, E. Morel, P. Díaz-Rosales, C. Tafalla, Functional and Phenotypic

- 1051 Characterization of B Cells in the Teleost Adipose Tissue. *Front. Immunol.* **13**, 2142 (2022).
- 1052 28. L. E. Swaim, L. E. Connolly, H. E. Volkman, O. Humbert, D. E. Born, L. Ramakrishnan,
1053 Mycobacterium marinum infection of adult zebrafish causes caseating granulomatous
1054 tuberculosis and is moderated by adaptive immunity. *Infect. Immun.* **74**, 6108–17 (2006).
- 1055 29. N. C. Steinel, D. I. Bolnick, Melanomacrophage centers as a histological indicator of immune
1056 function in fish and other poikilotherms. *Front. Immunol.* **8** (2017), ,
1057 doi:10.3389/fimmu.2017.00827.
- 1058 30. I. Salinas, The mucosal immune system of teleost fish. *Biology (Basel)*. **4** (2015), pp. 525–539.
- 1059 31. Y. Yu, Q. Wang, Z. Huang, L. Ding, Z. Xu, Immunoglobulins, Mucosal Immunity and Vaccination
1060 in Teleost Fish. *Front. Immunol.* **11** (2020), p. 2597.
- 1061 32. C. M. L. Press, O. Evensen, The morphology of the immune system in teleost fishes. *Fish
1062 Shellfish Immunol.* **9** (1999), doi:10.1006/fsim.1998.0181.
- 1063 33. Y. A. Zhang, I. Salinas, J. Li, D. Parra, S. Bjork, Z. Xu, S. E. Lapatra, J. Bartholomew, J. O. Sunyer,
1064 IgT, a primitive immunoglobulin class specialized in mucosal immunity. *Nat. Immunol.* **11**
1065 (2010), doi:10.1038/ni.1913.
- 1066 34. Z. Xu, D. Parra, D. Gómez, I. Salinas, Y. A. Zhang, L. Von Gersdorff Jørgensen, R. D. Heinecke, K.
1067 Buchmann, S. LaPatra, J. Oriol Sunyer, Teleost skin, an ancient mucosal surface that elicits gut-
1068 like immune responses. *Proc. Natl. Acad. Sci. U. S. A.* **110**, 13097–13102 (2013).
- 1069 35. L. Tacchi, R. Musharrafieh, E. T. Larragoite, K. Crossey, E. B. Erhardt, S. A. M. Martin, S. E.
1070 Lapatra, I. Salinas, Nasal immunity is an ancient arm of the mucosal immune system of
1071 vertebrates. *Nat. Commun.* **5** (2014), doi:10.1038/ncomms6205.
- 1072 36. A. S. Dalum, A. Kraus, S. Khan, E. Davydova, D. Rigau, H. Bjørgen, A. López-Porras, G.
1073 Griffiths, G. F. Wiegertjes, E. O. Koppang, I. Salinas, P. Boudinot, J. Rességuier, High-
1074 Resolution, 3D Imaging of the Zebrafish Gill-Associated Lymphoid Tissue (GIALT) Reveals a
1075 Novel Lymphoid Structure, the Amphibranchial Lymphoid Tissue. *Front. Immunol.* **12** (2021),
1076 doi:10.3389/fimmu.2021.769901.
- 1077 37. Y. Y. Yu, W. G. Kong, H. Y. Xu, Z. Y. Huang, X. T. Zhang, L. G. Ding, S. Dong, G. M. Yin, F. Dong,
1078 W. Yu, J. F. Cao, K. F. Meng, X. Liu, Y. Fu, X. zhen Zhang, Y. an Zhang, J. O. Sunyer, Z. Xu,
1079 Convergent Evolution of Mucosal Immune Responses at the Buccal Cavity of Teleost Fish.
1080 *iScience.* **19** (2019), doi:10.1016/j.isci.2019.08.034.
- 1081 38. W. Kong, Y. Yu, S. Dong, Z. Huang, L. Ding, J. Cao, F. Dong, X. Zhang, X. Liu, H. Xu, K. Meng, J.
1082 Su, Z. Xu, Pharyngeal Immunity in Early Vertebrates Provides Functional and Evolutionary
1083 Insight into Mucosal Homeostasis. *J. Immunol.* **203** (2019), doi:10.4049/jimmunol.1900863.
- 1084 39. H. RD, C. E, S. I, Molecular Drivers of Lymphocyte Organization in Vertebrate Mucosal
1085 Surfaces: Revisiting the TNF Superfamily Hypothesis. *J. Immunol.* **204**, 2697–2711 (2020).
- 1086 40. D. Parra, F. E. Reyes-Lopez, L. Tort, Mucosal Immunity and B Cells in Teleosts: Effect of
1087 Vaccination and Stress. *Front. Immunol.* **6**, 354 (2015).
- 1088 41. Ø. Bergh, K. Y. Børsheim, G. Bratbak, M. Heldal, High abundance of viruses found in aquatic
1089 environments. *Nature.* **340**, 467–468 (1989).
- 1090 42. E. Haugarvoll, I. Bjerkås, B. F. Nowak, I. Hordvik, E. O. Koppang, Identification and
1091 characterization of a novel intraepithelial lymphoid tissue in the gills of Atlantic salmon. *J.
1092 Anat.* **213**, 202–9 (2008).

- 1093 43. J. Sprague, L. Bayraktaroglu, D. Clements, T. Conlin, D. Fashena, K. Frazer, M. Haendel, D. G.
1094 Howe, P. Mani, S. Ramachandran, K. Schaper, E. Segerdell, P. Song, B. Sprunger, S. Taylor, C. E.
1095 Van Slyke, M. Westerfield, The Zebrafish Information Network: the zebrafish model organism
1096 database. *Nucleic Acids Res.* **34** (2006), doi:10.1093/nar/gkj086.
- 1097 44. R. L. Bailone, H. C. S. Fukushima, B. H. Ventura Fernandes, L. K. De Aguiar, T. Corrêa, H. Janke,
1098 P. Grejo Setti, R. D. O. Roça, R. C. Borra, Zebrafish as an alternative animal model in human
1099 and animal vaccination research. *Lab. Anim. Res.* **36** (2020), doi:10.1186/s42826-020-00042-4.
- 1100 45. C. K. Kaufman, C. Mosimann, Z. P. Fan, S. Yang, A. J. Thomas, J. Ablain, J. L. Tan, R. D. Fogley, E.
1101 Van Rooijen, E. J. Hagedorn, C. Ciarlo, R. M. White, D. A. Matos, A.-C. Puller, C. Santoriello, E.
1102 C. Liao, R. A. Young, L. I. Zon, A zebrafish melanoma model reveals emergence of neural crest
1103 identity during melanoma initiation, doi:10.1126/science.aad2197.
- 1104 46. G. Passoni, C. Langevin, N. Palha, B. C. Mounce, V. Briolat, P. Affaticati, E. De Job, J.-S. Joly, M.
1105 Vignuzzi, M.-C. Saleh, P. Herbomel, P. Boudinot, J.-P. Levrud, Imaging of viral neuroinvasion
1106 in the zebrafish reveals that Sindbis and chikungunya viruses favour different entry routes.
1107 *Dis. Model. Mech.* **10**, 847–857 (2017).
- 1108 47. É. Dóró, S. H. Jacobs, F. R. Hammond, H. Schipper, R. P. M. Pieters, M. Carrington, G. F.
1109 Wiegertjes, M. Forlenza, Visualizing trypanosomes in a vertebrate host reveals novel
1110 swimming behaviours, adaptations and attachment mechanisms. *Elife.* **8** (2019),
1111 doi:10.7554/eLife.48388.
- 1112 48. L. von G. Jørgensen, Zebrafish as a model for fish diseases in aquaculture. *Pathogens.* **9**
1113 (2020), pp. 1–20.
- 1114 49. S. C. Farina, T. J. Near, W. E. Bemis, Evolution of the branchiostegal membrane and restricted
1115 gill openings in Actinopterygian fishes. *J. Morphol.* **276**, 681–694 (2015).
- 1116 50. A. Castillo, P. López-Fierro, A. Zapata, A. Villena, B. Razquin, Post-hatching development of the
1117 thymic epithelial cells in the rainbow trout *Salmo gairdneri*: An ultrastructural study. *Am. J.*
1118 *Anat.* **190**, 299–307 (1991).
- 1119 51. A. C. Chan, M. Iwashima, C. W. Turck, A. Weiss, ZAP-70: A 70 kd protein-tyrosine kinase that
1120 associates with the TCR ζ chain. *Cell.* **71**, 649–662 (1992).
- 1121 52. J. Rességuier, A. S. Dalum, L. Du Pasquier, Y. Zhang, E. O. Koppang, P. Boudinot, G. F.
1122 Wiegertjes, Lymphoid Tissue in Teleost Gills: Variations on a Theme. *Biology (Basel).* **9**, 127
1123 (2020).
- 1124 53. W. W. Franke, R. Moll, Cytoskeletal components of lymphoid organs. *Differentiation.* **36**, 145–
1125 163 (1987).
- 1126 54. T. Katakai, T. Hara, J. H. Lee, H. Gonda, M. Sugai, A. Shimizu, A novel reticular stromal
1127 structure in lymph node cortex: an immuno-platform for interactions among dendritic cells, T
1128 cells and B cells. *Int. Immunol.* **16**, 1133–1142 (2004).
- 1129 55. E. Haugarvoll, I. Bjerås, B. F. Nowak, I. Hordvik, E. O. Koppang, Identification and
1130 characterization of a novel intraepithelial lymphoid tissue in the gills of Atlantic salmon. *J.*
1131 *Anat.* **213**, 202–209 (2008).
- 1132 56. D. Malhotra, A. L. Fletcher, J. Astarita, V. Lukacs-Kornek, P. Tayalia, S. F. Gonzalez, K. G. Elpek,
1133 S. K. Chang, K. Knoblich, M. E. Hemler, M. B. Brenner, M. C. Carroll, D. J. Mooney, S. J. Turley,
1134 Y. Zhou, S. A. Shinton, R. R. Hardy, N. A. Bezman, J. C. Sun, C. C. Kim, L. L. Lanier, J. Miller, B.
1135 Brown, M. Merad, A. Bellemare-Pelletier, K. Narayan, K. Sylvia, J. Kang, R. Gazit, B. Garrison,
1136 D. J. Rossi, V. Jojic, D. Koller, R. Jianu, D. Laidlaw, J. Costello, J. Collins, N. Cohen, P. Brennan, T.

- 1137 Shay, A. Regev, F. Kim, T. N. Rao, A. Wagers, E. L. Gautier, C. Jakubzick, G. J. Randolph, P.
1138 Monach, A. J. Best, J. Knell, A. Goldrath, T. Heng, T. Kreslavsky, M. Painter, D. Mathis, C.
1139 Benoist, Transcriptional profiling of stroma from inflamed and resting lymph nodes defines
1140 immunological hallmarks. *Nat. Immunol.* 2012 135. **13**, 499–510 (2012).
- 1141 57. N. D. Lawson, B. M. Weinstein, In Vivo Imaging of Embryonic Vascular Development Using
1142 Transgenic Zebrafish. *Dev. Biol.* **248**, 307–318 (2002).
- 1143 58. T. Seternes, K. Sørensen, B. Smedsrød, Scavenger endothelial cells of vertebrates: A
1144 nonperipheral leukocyte system for high-capacity elimination of waste macromolecules. *Proc.*
1145 *Natl. Acad. Sci. U. S. A.* **99** (2002), doi:10.1073/pnas.102173299.
- 1146 59. J. P. Girard, T. A. Springer, High endothelial venules (HEVs): specialized endothelium for
1147 lymphocyte migration. *Immunol. Today.* **16**, 449–457 (1995).
- 1148 60. R. Burne, I. A contribution to the anatomy of the ductless glands and lymphatic system of the
1149 angler fish (*Lophius piscatorius*). *Philos. Trans. R. Soc. London. Ser. B, Contain. Pap. a Biol.*
1150 *Character.* **215**, 1–56 (1927).
- 1151 61. J. M. Wilson, P. Laurent, Fish gill morphology: inside out. *J. Exp. Zool.* **293**, 192–213 (2002).
- 1152 62. D. M. Langenau, A. A. Ferrando, D. Traver, J. L. Kutok, J. P. D. Hezel, J. P. Kanki, L. I. Zon, A.
1153 Thomas Look, N. S. Trede, In vivo tracking of T cell development, ablation, and engraftment in
1154 transgenic zebrafish. *Proc. Natl. Acad. Sci. U. S. A.* **101**, 7369–7374 (2004).
- 1155 63. S. A. Renshaw, C. A. Loynes, D. M. I. Trushell, S. Elworthy, P. W. Ingham, M. K. B. Whyte, A
1156 transgenic zebrafish model of neutrophilic inflammation. *Blood.* **108**, 3976–8 (2006).
- 1157 64. V. Wittamer, J. Y. Bertrand, P. W. Gutschow, D. Traver, Characterization of the mononuclear
1158 phagocyte system in zebrafish. *Blood.* **117**, 7126–35 (2011).
- 1159 65. Q. T. Phan, T. Sipka, C. Gonzalez, J.-P. Levraud, G. Lutfalla, M. Nguyen-Chi, Neutrophils use
1160 superoxide to control bacterial infection at a distance. *PLOS Pathog.* **14**, e1007157 (2018).
- 1161 66. J. Rességuier, E. Delaune, A.-L. Coolen, J.-P. Levraud, P. Boudinot, D. Le Guellec, B. Verrier,
1162 Specific and Efficient Uptake of Surfactant-Free Poly(Lactic Acid) Nanovaccine Vehicles by
1163 Mucosal Dendritic Cells in Adult Zebrafish after Bath Immersion. *Front. Immunol.* **8**, 190
1164 (2017).
- 1165 67. L. A. Lampson, R. Levy, Two populations of Ia-like molecules on a human B cell line. *J.*
1166 *Immunol.* **125** (1980).
- 1167 68. M. de Weers, M. C. M. Verschuren, M. E. M. Kraakman, R. G. J. Mensink, R. K. B. Schuurman, J.
1168 J. M. van Dongen, R. W. Hendriks, The Bruton’s tyrosine kinase gene is expressed throughout
1169 B cell differentiation, from early precursor B cell stages preceding immunoglobulin gene
1170 rearrangement up to mature B cell stages. *Eur. J. Immunol.* **23**, 3109–3114 (1993).
- 1171 69. H. C. Genevier, S. Hinshelwood, H. B. Gaspar, K. P. Rigley, D. Brown, S. Saeland, F. Rousset, R.
1172 J. Levinsky, R. E. Callard, C. Kinnon, R. C. Lovering, Expression of Bruton’s tyrosine kinase
1173 protein within the B cell lineage. *Eur. J. Immunol.* **24**, 3100–3105 (1994).
- 1174 70. J. N. Gabhann, E. Hams, S. Smith, C. Wynne, J. C. Byrne, K. Brennan, S. Spence, A.
1175 Kissenpfennig, J. A. Johnston, P. G. Fallon, C. A. Jefferies, Btk Regulates Macrophage
1176 Polarization in Response to Lipopolysaccharide. *PLoS One.* **9**, e85834 (2014).
- 1177 71. D. M. Page, V. Wittamer, J. Y. Bertrand, K. L. Lewis, D. N. Pratt, N. Delgado, S. E. Schale, C.
1178 McGue, B. H. Jacobsen, A. Doty, Y. Pao, H. Yang, N. C. Chi, B. G. Magor, D. Traver, An
1179 evolutionarily conserved program of B-cell development and activation in zebrafish. *Blood.*

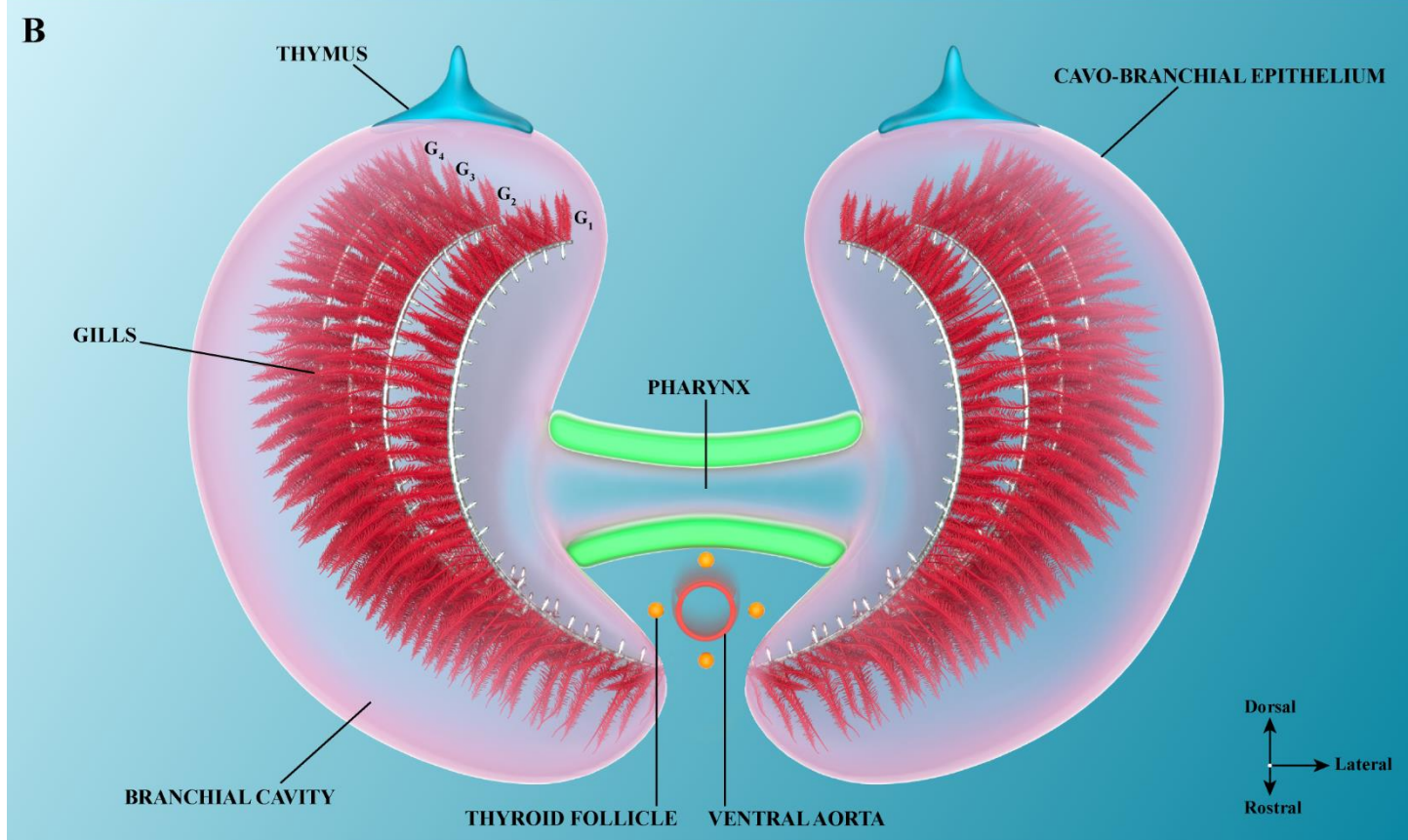
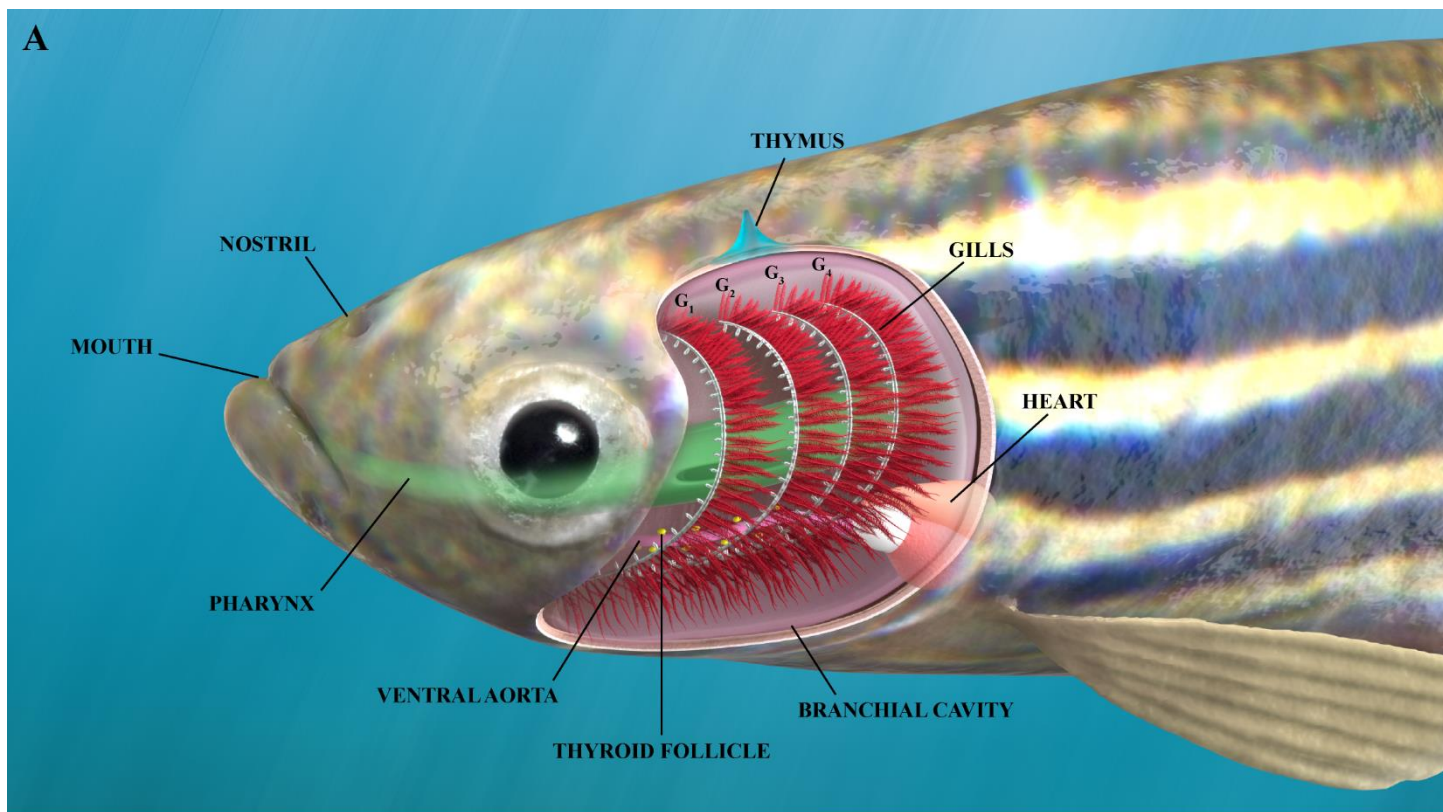
- 1180 **122**, e1-11 (2013).
- 1181 72. D. M. Langenau, M. D. Keefe, N. Y. Storer, J. R. Guyon, J. L. Kutok, X. Le, W. Goessling, D. S.
1182 Neuberg, L. M. Kunkel, L. I. Zon, Effects of RAS on the genesis of embryonal
1183 rhabdomyosarcoma. *Genes Dev.* **21**, 1382–1395 (2007).
- 1184 73. I. B. Aas, L. Austbø, M. König, M. Syed, K. Falk, I. Hordvik, E. O. Koppang, Transcriptional
1185 Characterization of the T Cell Population within the Salmonid Interbranchial Lymphoid Tissue.
1186 *J. Immunol.* **193**, 3463–3469 (2014).
- 1187 74. D. Ma, J. Zhang, H. F. Lin, J. Italiano, R. I. Handin, The identification and characterization of
1188 zebrafish hematopoietic stem cells. *Blood.* **118**, 289–297 (2011).
- 1189 75. T. M. Holling, E. Schooten, P. J. Van Den Elsen, Function and regulation of MHC class II
1190 molecules in T-lymphocytes: of mice and men. *Hum. Immunol.* **65**, 282–290 (2004).
- 1191 76. J. H. Phillips, A. M. Le, L. L. Lanier, Natural killer cells activated in a human mixed lymphocyte
1192 response culture identified by expression of Leu-11 and class II histocompatibility antigens. *J.*
1193 *Exp. Med.* **159**, 993–1008 (1984).
- 1194 77. A. K. Mehta, D. T. Gracias, M. Croft, TNF Activity and T cells. *Cytokine.* **101**, 14 (2018).
- 1195 78. M. Nguyen-Chi, B. Laplace-Builhe, J. Travnickova, P. Luz-Crawford, G. Tejedor, Q. T. Phan, I.
1196 Duroux-Richard, J. P. Levrard, K. Kissa, G. Lutfalla, C. Jorgensen, F. Djouad, Identification of
1197 polarized macrophage subsets in zebrafish. *Elife.* **4** (2015), doi:10.7554/eLife.07288.
- 1198 79. M. L. Kent, C. Harper, J. C. Wolf, Documented and Potential Research Impacts of Subclinical
1199 Diseases in Zebrafish. *ILAR J.* **53**, 126–134 (2012).
- 1200 80. S. L.-J. of A. A. Health, undefined 1998, Factors affecting pathogenicity of infectious
1201 hematopoietic necrosis virus (IHNV) for salmonid fish. *Taylor Fr.* **10**, 121–131 (1998).
- 1202 81. S. E. La Patra, L. Barone, G. R. Jones, L. I. Zon, Effects of Infectious Hematopoietic Necrosis
1203 Virus and Infectious Pancreatic Necrosis Virus Infection on Hematopoietic Precursors of the
1204 Zebrafish. *Blood Cells, Mol. Dis.* **26**, 445–452 (2000).
- 1205 82. W. AHNE, Uptake and multiplication of spring viraemia of carp virus in carp, *Cyprinus carpio* L.
1206 *J. Fish Dis.* **1**, 265–268 (1978).
- 1207 83. G. Sanders, W. Batts, J. W.-C. Medicine, U. 2003, Susceptibility of zebrafish (*Danio rerio*) to a
1208 model pathogen, spring viremia of carp virus. *Comp. Med.* **53**, 514-521(8) (2003).
- 1209 84. W. S. Hoar, The thyroid gland of the Atlantic salmon. *J. Morphol.* **65**, 257–295 (1939).
- 1210 85. C. G. Furin, F. A. von Hippel, J. H. Postlethwait, C. L. Buck, W. A. Cresko, T. M. O’Hara,
1211 Developmental timing of sodium perchlorate exposure alters angiogenesis, thyroid follicle
1212 proliferation and sexual maturation in stickleback. *Gen. Comp. Endocrinol.* **219**, 24–35 (2015).
- 1213 86. C. E. Willett, A. G. Zapata, N. Hopkins, L. A. Steiner, Expression of ZebrafishragGenes during
1214 Early Development Identifies the Thymus. *Dev. Biol.* **182**, 331–341 (1997).
- 1215 87. A. Zapata, B. Diez, T. Cejalvo, C. Gutiérrez-De Frías, A. Cortés, Ontogeny of the immune system
1216 of fish. *Fish Shellfish Immunol.* **20**, 126–136 (2006).
- 1217 88. S. H. Lam, H. L. Chua, Z. Gong, T. J. Lam, Y. M. Sin, Development and maturation of the
1218 immune system in zebrafish, *Danio rerio*: a gene expression profiling, in situ hybridization and
1219 immunological study. *Dev. Comp. Immunol.* **28**, 9–28 (2004).
- 1220 89. P. De Vito, S. Incerpi, J. Z. Pedersen, P. Luly, F. B. Davis, P. J. Davis, Thyroid hormones as

- 1221 modulators of immune activities at the cellular level. *Thyroid*. **21**, 879–890 (2011).
- 1222 90. R. De Luca, P. J. Davis, H. Y. Lin, F. Gionfra, Z. A. Percario, E. Affabris, J. Z. Pedersen, C.
1223 Marchese, P. Trivedi, E. Anastasiadou, R. Negro, S. Incerpi, Thyroid Hormones Interaction With
1224 Immune Response, Inflammation and Non-thyroidal Illness Syndrome. *Front. Cell Dev. Biol.* **8**,
1225 1775 (2021).
- 1226 91. N. Fabris, Immunodepression in thyroid-deprived animals. *Clin. Exp. Immunol.* **15**, 601 (1973).
- 1227 92. D. D. Brown, The role of thyroid hormone in zebrafish and axolotl development. *Proc. Natl.*
1228 *Acad. Sci. U. S. A.* **94**, 13011–13016 (1997).
- 1229 93. S. . Lam, H. . Chua, Z. Gong, T. . Lam, Y. . Sin, Development and maturation of the immune
1230 system in zebrafish, *Danio rerio*: a gene expression profiling, in situ hybridization and
1231 immunological study. *Dev. Comp. Immunol.* **28**, 9–28 (2004).
- 1232 94. S. H. Lam, Y. M. Sin, Z. Gong, T. J. Lam, Effects of thyroid hormone on the development of
1233 immune system in zebrafish. *Gen. Comp. Endocrinol.* **142**, 325–335 (2005).
- 1234 95. S. A. van de Pavert, Lymphoid Tissue inducer (LTi) cell ontogeny and functioning in embryo
1235 and adult. *Biomed. J.* **44** (2021), , doi:10.1016/j.bj.2020.12.003.
- 1236 96. W. Waldeyer, Über denlymphatischen apparat dès Pharynx. *Dtsch Med Wochenschr.* **10**, 313
1237 (1884).
- 1238 97. J. A. Hammar, Studien über die Entwicklung des Vorder-darms und einiger angrenzenden
1239 Organe: Hierzu Tafel XXI und XXII. *Arch. für mikroskopische Anat.* **61**, 404–458 (1902).
- 1240 98. J. Slópka, Palatine Tonsils—Their Evolution and Ontogeny.
1241 <http://dx.doi.org/10.3109/00016488809124998>. **105**, 18–22 (2009).
- 1242 99. G. Isaacson, T. Parikh, Developmental anatomy of the tonsil and its implications for
1243 intracapsular tonsillectomy. *Int. J. Pediatr. Otorhinolaryngol.* **72**, 89–96 (2008).
- 1244 100. K. Okada, S. Takada, The second pharyngeal pouch is generated by dynamic remodeling of
1245 endodermal epithelium in zebrafish. *Dev.* **147** (2020), doi:10.1242/DEV.194738/VIDEO-2.
- 1246 101. Q. Tang, N. S. Abdelfattah, J. S. Blackburn, J. C. Moore, S. A. Martinez, F. E. Moore, R.
1247 Lobbardi, I. M. Tenente, M. S. Ignatius, J. N. Berman, R. S. Liwski, Y. Houvras, D. M. Langenau,
1248 Optimized cell transplantation using adult rag2 mutant zebrafish. *Nat. Methods* **11**,
1249 821–824 (2014).
- 1250 102. Z. Xu, F. Takizawa, E. Casadei, Y. Shibasaki, Y. Ding, T. J. C. Sauters, Y. Yu, I. Salinas, J. O.
1251 Sunyer, Specialization of mucosal immunoglobulins in pathogen control and microbiota
1252 homeostasis occurred early in vertebrate evolution. *Sci. Immunol.* **5**, 3254 (2020).
- 1253 103. A. Muthupandian, D. Waly, B. G. Magor, Do ectothermic vertebrates have a home in which to
1254 affinity mature their antibody responses? *Dev. Comp. Immunol.* **119** (2021),
1255 doi:10.1016/J.DCI.2021.104021.
- 1256 104. I. B. Aas, L. Austbø, K. Falk, I. Hordvik, E. O. Koppang, The interbranchial lymphoid tissue likely
1257 contributes to immune tolerance and defense in the gills of Atlantic salmon. *Dev. Comp.*
1258 *Immunol.* **76**, 247–254 (2017).
- 1259 105. L. Austbø, I. B. Aas, M. König, S. C. Weli, M. Syed, K. Falk, E. O. Koppang, Transcriptional
1260 response of immune genes in gills and the interbranchial lymphoid tissue of Atlantic salmon
1261 challenged with infectious salmon anaemia virus. *Dev. Comp. Immunol.* **45**, 107–114 (2014).
- 1262 106. S. W. Jin, D. Beis, T. Mitchell, J. N. Chen, D. Y. R. Stainier, Cellular and molecular analyses of

- 1263 vascular tube and lumen formation in zebrafish. *Development*. **132** (2005),
1264 doi:10.1242/dev.02087.
- 1265 107. K. S. Okuda, J. W. Astin, J. P. Misa, M. V. Flores, K. E. Crosier, P. S. Crosier, Lyve1 expression
1266 reveals novel lymphatic vessels and new mechanisms for lymphatic vessel development in
1267 zebrafish. *Dev*. **139** (2012), doi:10.1242/dev.077701.
- 1268 108. C. W. E. Embregts, D. Rigaudeau, T. Veselý, D. Pokorová, N. Lorenzen, J. Petit, A. Houel, M.
1269 Dauber, H. Schütze, P. Boudinot, G. F. Wiegertjes, M. Forlenza, Intramuscular DNA vaccination
1270 of juvenile carp against spring viremia of carp virus induces full protection and Establishes
1271 a Virus-Specific B and T Cell Response. *Front. Immunol.* **8** (2017),
1272 doi:10.3389/fimmu.2017.01340.
- 1273 109. D. Aggad, M. Mazel, P. Boudinot, K. E. Mogensen, O. J. Hamming, R. Hartmann, S. Kotenko, P.
1274 Herbomel, G. Lutfalla, J.-P. Levraud, The two groups of zebrafish virus-induced interferons
1275 signal via distinct receptors with specific and shared chains. *J. Immunol.* **183**, 3924–3931
1276 (2009).
- 1277 110. M. Schliwa, J. Van Blerkom, Structural interaction of cytoskeletal components. *J. Cell Biol.* **90**,
1278 222–235 (1981).
- 1279 111. J. Montanaro, D. Gruber, N. Leisch, Improved ultrastructure of marine invertebrates using
1280 non-toxic buffers. *PeerJ*. **2016** (2016), doi:10.7717/peerj.1860.
- 1281 112. R. L. Wood, J. H. Luft, The influence of buffer systems on fixation with osmium tetroxide. *J.*
1282 *Ultrastructure Res.* **12** (1965), doi:10.1016/S0022-5320(65)80004-1.
- 1283 113. T. S. Reese, M. J. Karnovsky, Fine structural localization of a blood-brain barrier to exogenous
1284 peroxidase. *J. Cell Biol.* **34** (1967), doi:10.1083/jcb.34.1.207.
- 1285 114. E. Carlemalm, W. Villiger, J. A. Hobot, J. -D Acetarin, E. Kellenberger, Low temperature
1286 embedding with Lowicryl resins: two new formulations and some applications. *J. Microsc.* **140**
1287 (1985), doi:10.1111/j.1365-2818.1985.tb02660.x.
- 1288 115. S. Al-Asheh, F. Banat, N. Al-Lagtah, Separation of ethanol-water mixtures using molecular
1289 sieves and biobased adsorbents. *Chem. Eng. Res. Des.* **82** (2004),
1290 doi:10.1205/0263876041596779.
- 1291 116. J. H. LUFT, Improvements in epoxy resin embedding methods. *J. Biophys. Biochem. Cytol.* **9**
1292 (1961), doi:10.1083/jcb.9.2.409.
- 1293 117. B. F. Trump, E. A. Smuckler, E. P. Benditt, A method for staining epoxy sections for light
1294 microscopy. *J. Ultrastructure Res.* **5** (1961), doi:10.1016/S0022-5320(61)80011-7.
- 1295 118. K. C. Richardson, L. Jarett, E. H. Finke, Embedding in epoxy resins for ultrathin sectioning in
1296 electron microscopy. *Biotech. Histochem.* **35** (1960), doi:10.3109/10520296009114754.
- 1297 119. J. G. STEMPAK, R. T. WARD, AN IMPROVED STAINING METHOD FOR ELECTRON MICROSCOPY.
1298 *J. Cell Biol.* **22** (1964), doi:10.1083/jcb.22.3.697.
- 1299 120. E. S. REYNOLDS, The use of lead citrate at high pH as an electron-opaque stain in electron
1300 microscopy. *J. Cell Biol.* **17** (1963), doi:10.1083/jcb.17.1.208.
- 1301 121. G. Griffiths, Quantitative Aspects of Immunocytochemistry. *Fine Struct. Immunocytochem.*,
1302 371–445 (1993).
- 1303

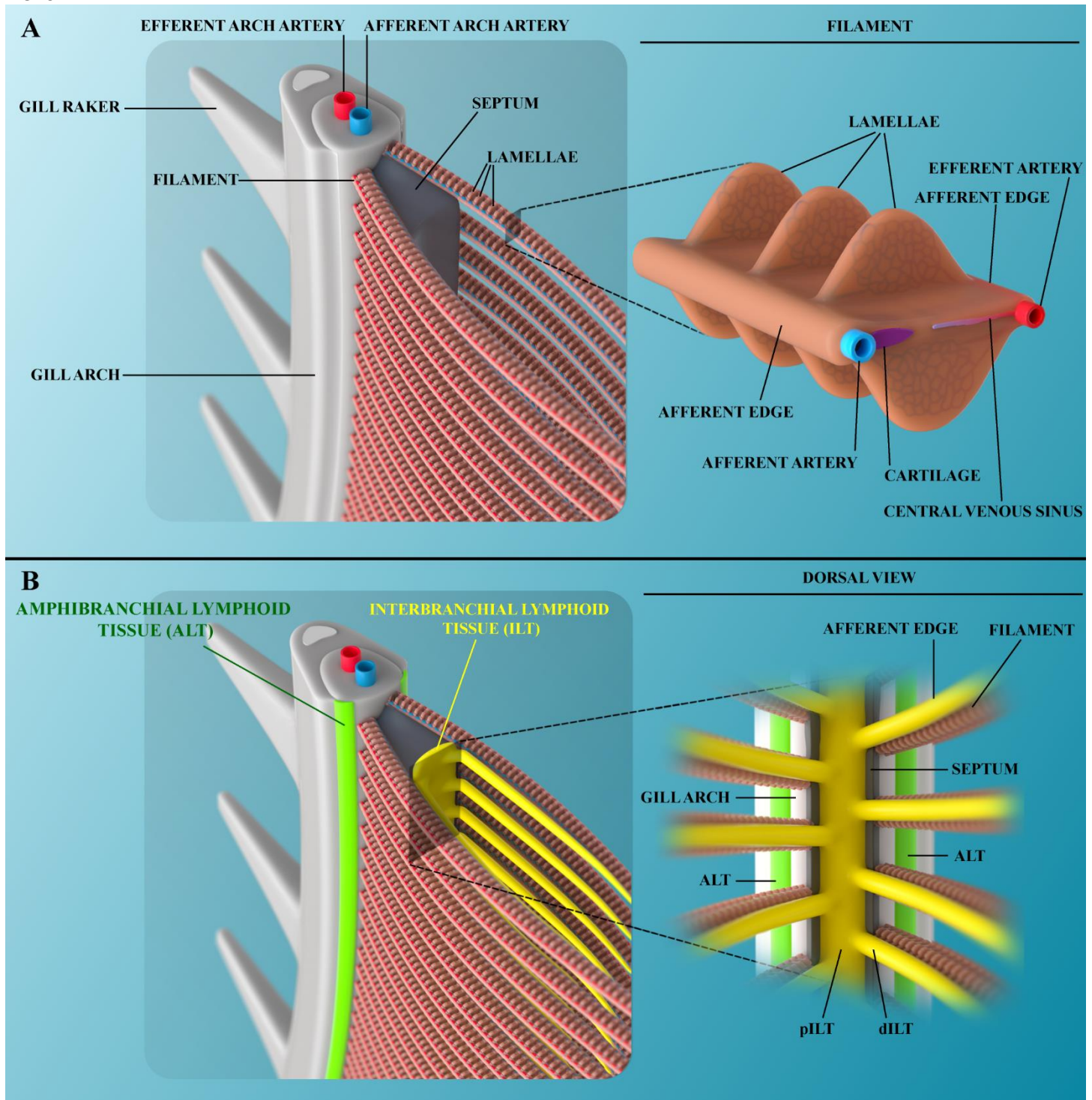
1304 SUPPLEMENTARY FIGURES AND VIDEO LEGENDS

1305



1306

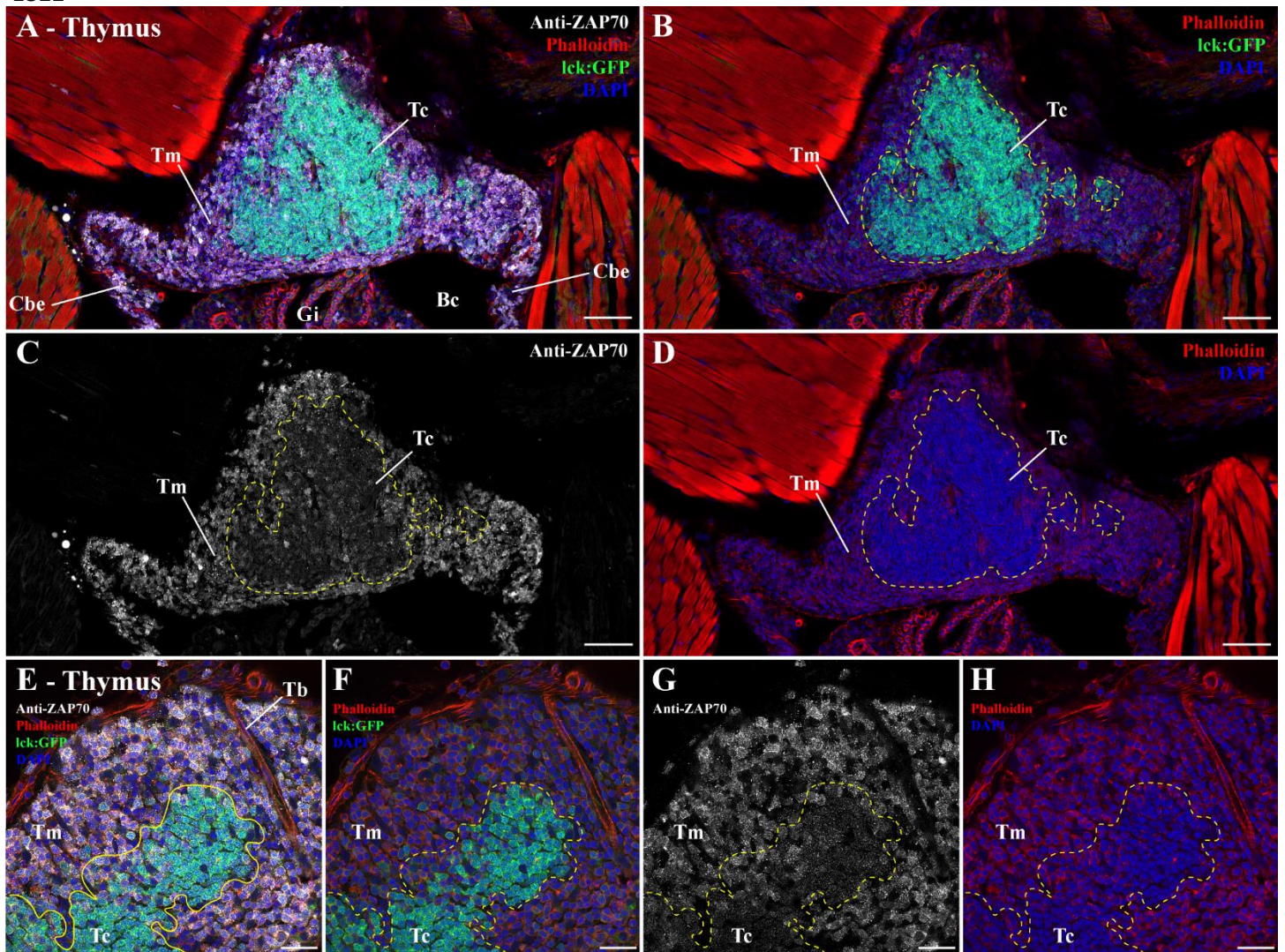
1307 **Figure S1 – Organization of the adult zebrafish branchial cavity.** Illustrations of the branchial cavity tissue
1308 organization as seen from the side (A) or from a front view (B). G₁₋₄: First to fourth gill arch. Illustrations made
1309 by Ella Maru studio.
1310



1311 **Figure S2 – Organization of the adult zebrafish gills.** Illustration of a gill arch (A) with its associated lymphoid
1312 tissues (B). Illustrations made by Ella Maru studio.
1313

1314
1315
1316
1317
1318

1319
1320
1321
1322



1323

1324

1325

1326

1327

1328

1329

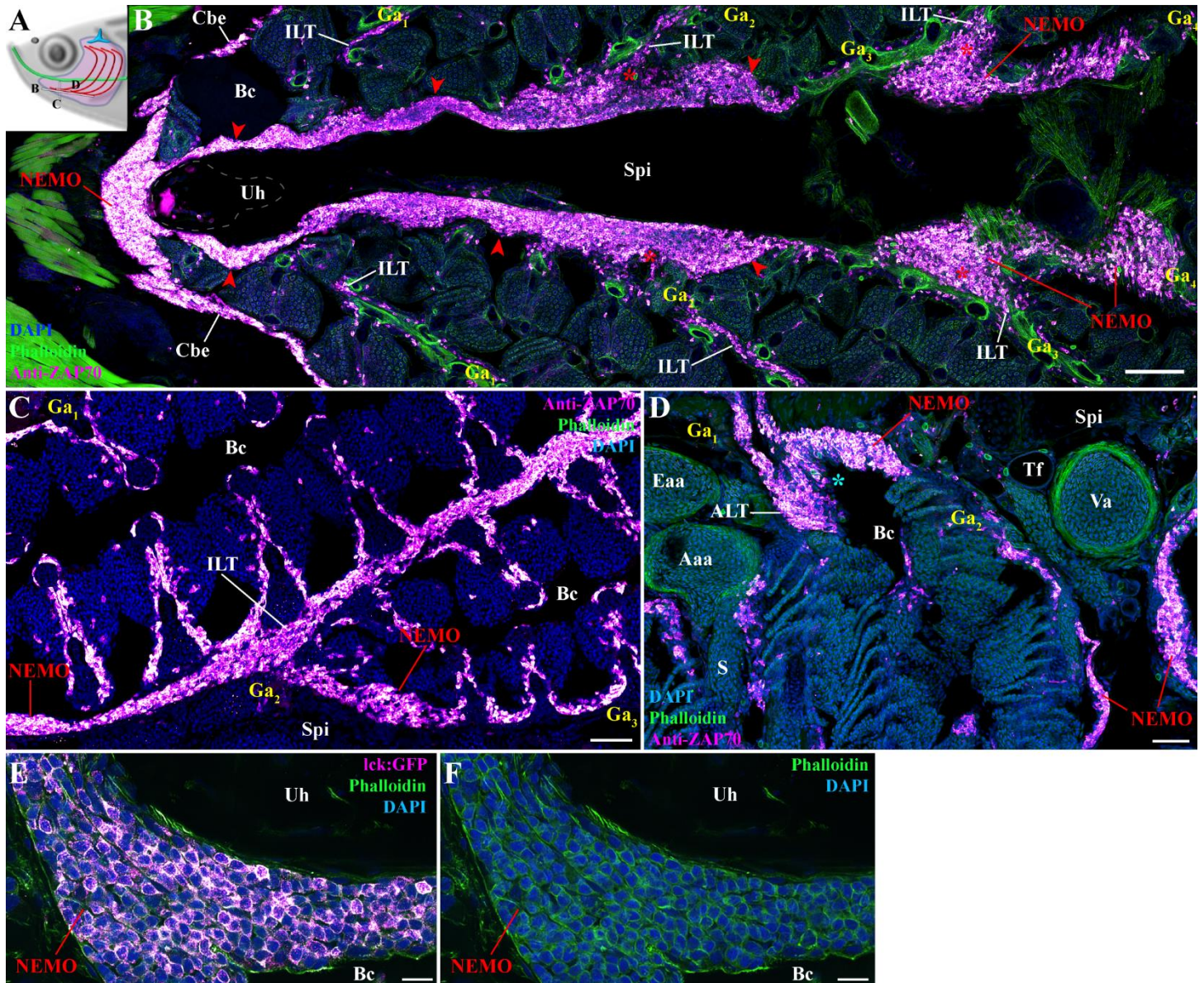
1330

1331

1332

1333

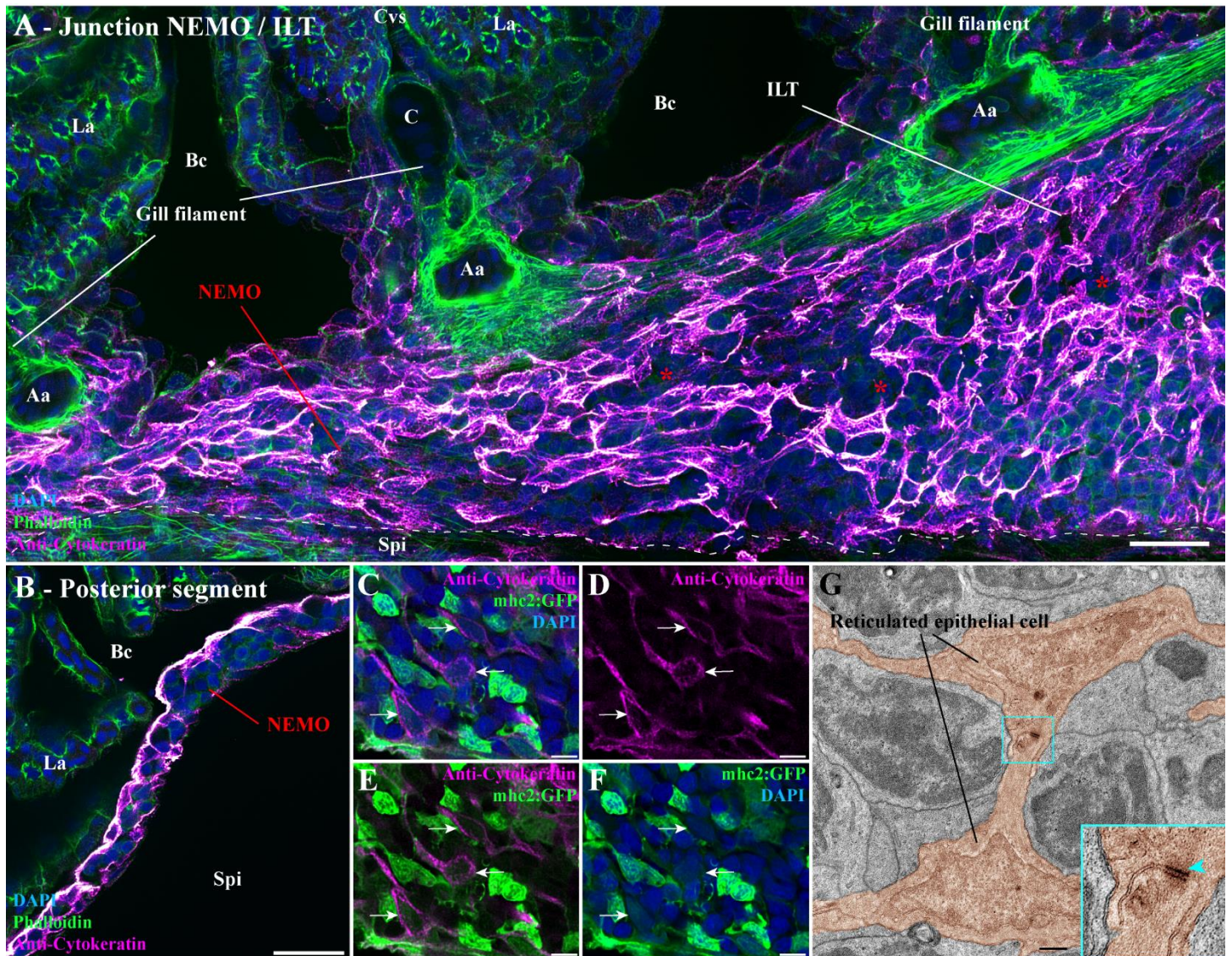
Figure S3 – Zebrafish thymus anti-ZAP70 labeling. (A-D) Cryosections from *lck:EGFP* adult zebrafish, in which T cells are fluorescent (green), labeled with anti-ZAP70 antibody (white). As expected, the thymus and its GFP-positive cells are labeled by the anti-ZAP70 labeling. In the thymus cortex thymocytes are intensely packed, highly express the gene *lck* and display a low anti-ZAP70 labeling. In contrast, the more developed thymocytes that populate the thymus medulla showed a low *lck* gene expression and high anti-ZAP70 labeling. This distinction is even more striking at higher magnification (E-H). Annotations: Bc, Branchial cavity; Cbe, Cavobranchial epithelium; Gi, Gills; Tb, Trabecula; Tc, Thymus cortex and Tm, Thymus medulla. Scale bars: 50 μ m (A-D) and 20 μ m (E-H).



1334
1335
1336

1337 **Figure S4 – Additional information on NEMO's identification.** (A) Scheme localizing the section planes of
1338 images (B-D). (B) Additional 3D multi-field of view image of an adult zebrafish NEMO from a branchial cavity
1339 coronal cryosection labeled with anti-ZAP70 (magenta hot). The structure corresponding to NEMO is highlighted
1340 by red arrowheads. Connection sites between NEMO and ILTs are marked by red stars. (C) Additional image
1341 illustrating the continuity between NEMO and an interbranchial lymphoid tissue. (D) Additional image illustration
1342 the connection between NEMO and an amphibranchial lymphoid tissue (cyan star). (E-F) NEMO cryosection from
1343 a lck:EGFP adult zebrafish, in which T cells are fluorescent (magenta hot). Annotations: Aaa, Afferent arch artery;
1344 ALT, Amphibranchial lymphoid tissue; Bc, Branchial cavity; Cbe, Cavobranchial epithelium; Eaa, Efferent arch
1345 artery; Ga, Gill arch; ILT, Interbranchial lymphoid tissue; S, Septum; Spi; Sub-pharyngeal isthmus; Tf, Thyroid
1346 follicle; Uh, Urohyal bone and Va, Ventral aorta. Scale bars: 100 μ m (B), 50 μ m (C,D), and 10 μ m (E,F).

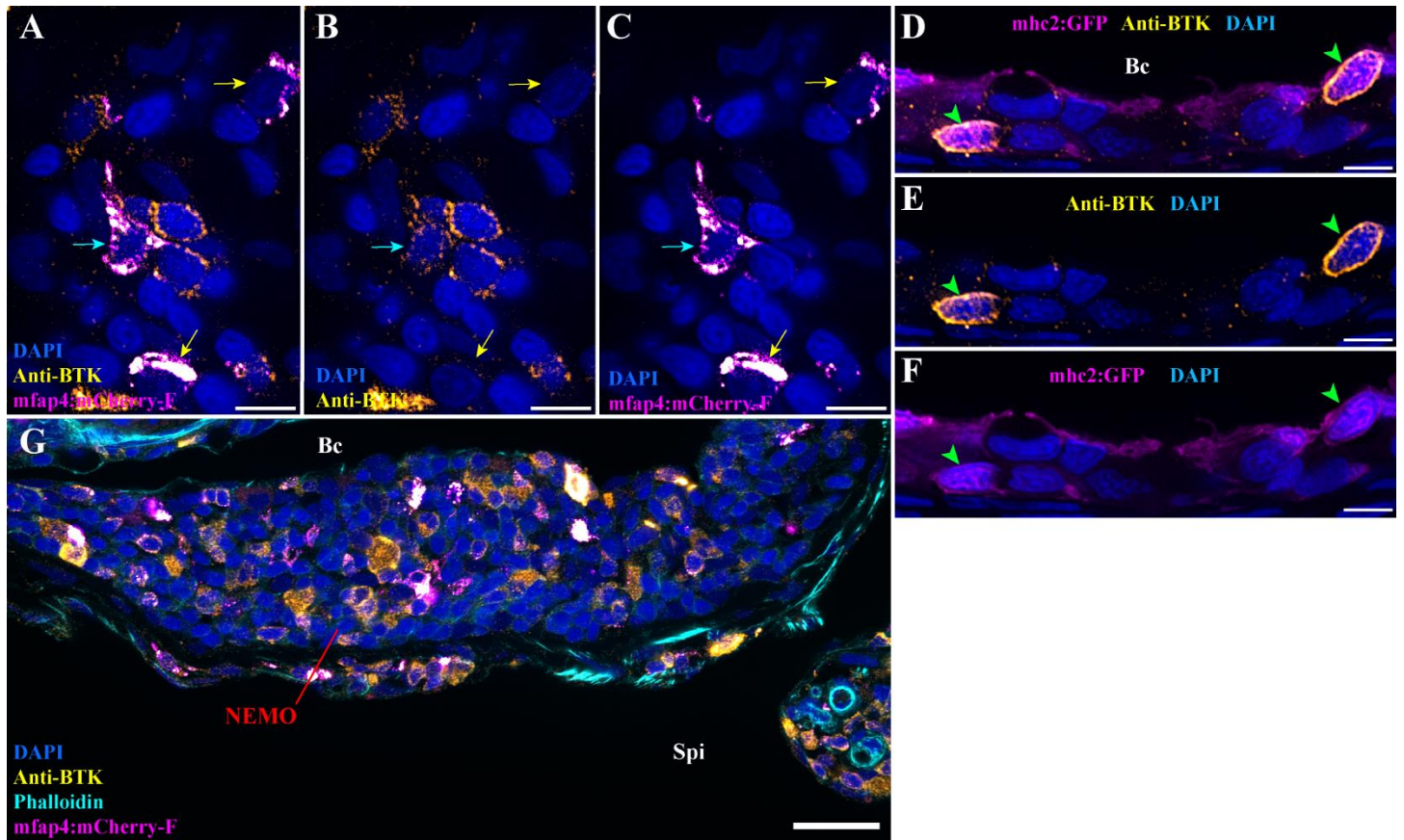
1347
1348
1349
1350
1351
1352
1353
1354



1355
1356
1357

1358 **Figure S5 – Additional information on NEMO's network of reticulated epithelial cells.** (A) Adult zebrafish
1359 cryosections labeling with anti-cytokeratin (magenta hot) display the connection site of NEMO with an ILT (red
1360 stars). (B) Network of reticulated epithelial cells at the posterior end of NEMO. (C-F) Cryosection from a
1361 *mhc2:GFP* adult zebrafish, in which *mhc2*-expressing cells are fluorescent (green), labeled with anti-cytokeratin
1362 (magenta hot). NEMO reticulated epithelial cells displayed a low *mhc2* expression (white arrows). (G) Zoomed
1363 transmission electron micrograph from the ultrastructure map of Figure 2 highlighting the presence of an
1364 hemidesmosome (cyan arrowhead) at the junction of two reticulated epithelial cells (orange). Annotations: Aa,
1365 Afferent artery; Bc, Branchial cavity; C, Cartilage; ILT, Interbranchial lymphoid tissue; La, Lamellae; Spi, Sub-
1366 Pharyngeal isthmus. Scale bars: 20 μm (A,B), 5 μm (C-F), and 500 nm (G).

1367
1368
1369
1370
1371
1372
1373
1374
1375
1376
1377



1378

1379

1380

1381

1382

1383

1384

1385

1386

Figure S6 – Additional information anti-BTK antibody labeling. (A-C) Anti-BTK labeling (orange hot) on mfap4:mCherry-F adult zebrafish cryosections, in which macrophage are fluorescent (magenta hot). Within NEMO, both BTK-positive (cyan arrows) and BTK-negative (yellow arrows) macrophages are observed. (D-F) Cryosection from an mhc2:GFP adult zebrafish NEMO, in which IgM expressing B cells are fluorescent (magenta hot), labeled with anti-BTK (orange hot). As expected, cells expressing IgM are also BTK-positive (green arrowheads). (G) Additional image displaying anti-BTK labeling in NEMO of a mfap4:mCherry-F adult zebrafish. Annotations: Bc, Branchial cavity and Spi, Sub-pharyngeal isthmus. Scale bars: 20 μm (G), and 5 μm (A-F).

1387

1388

1389

1390

1391

1392

1393

1394

1395

1396

1397

1398

1399

1400

1401

1402

1403

1404

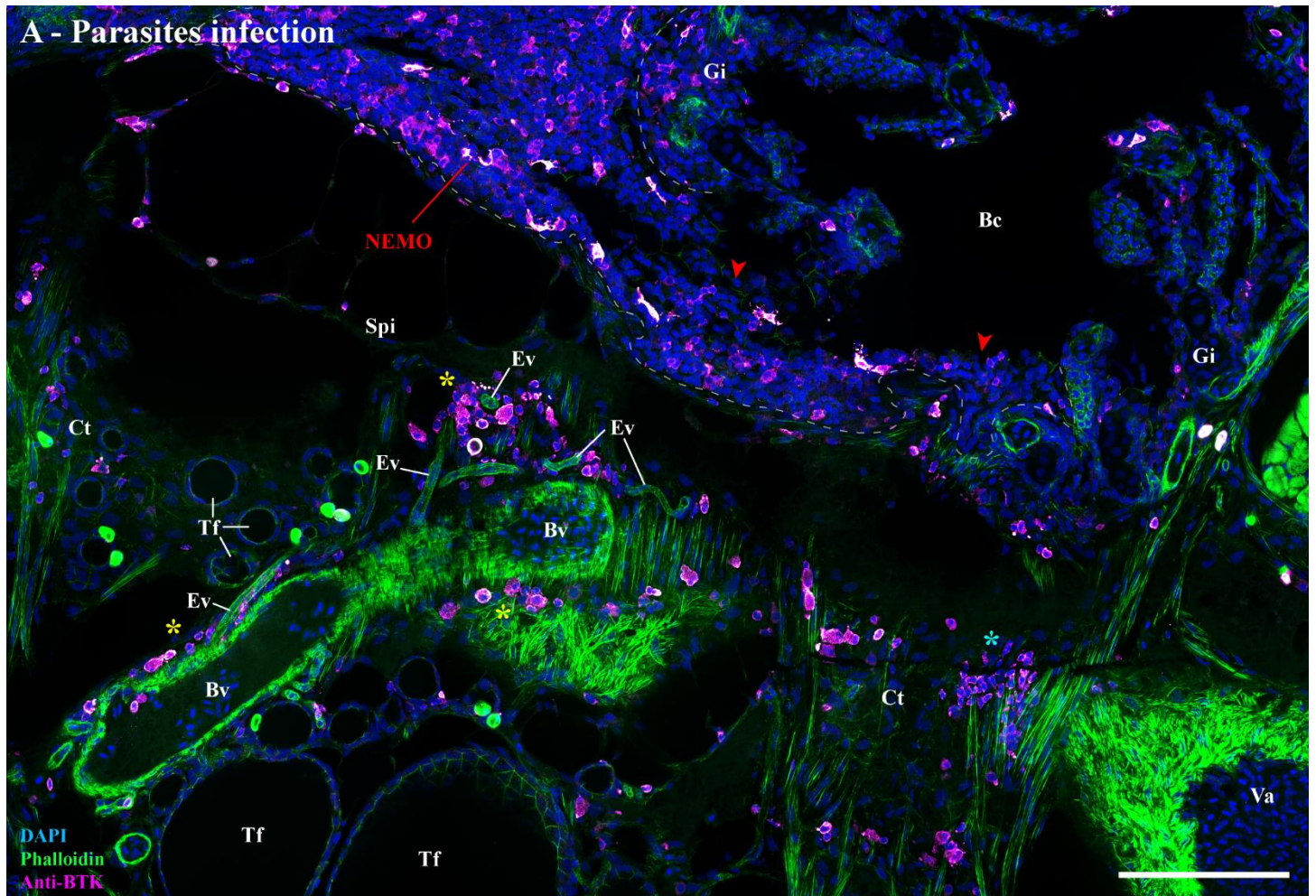
1405

1406

1407

1408

1409

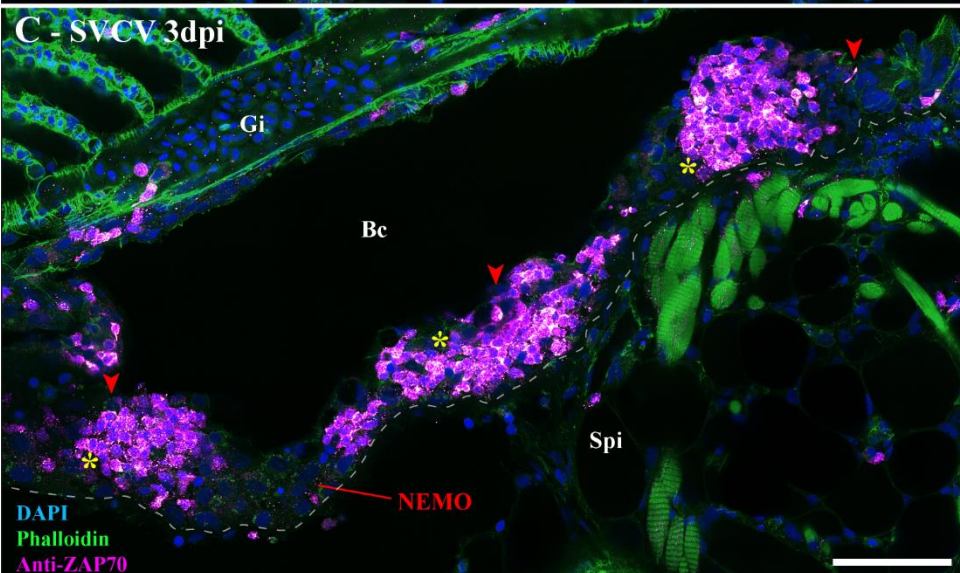
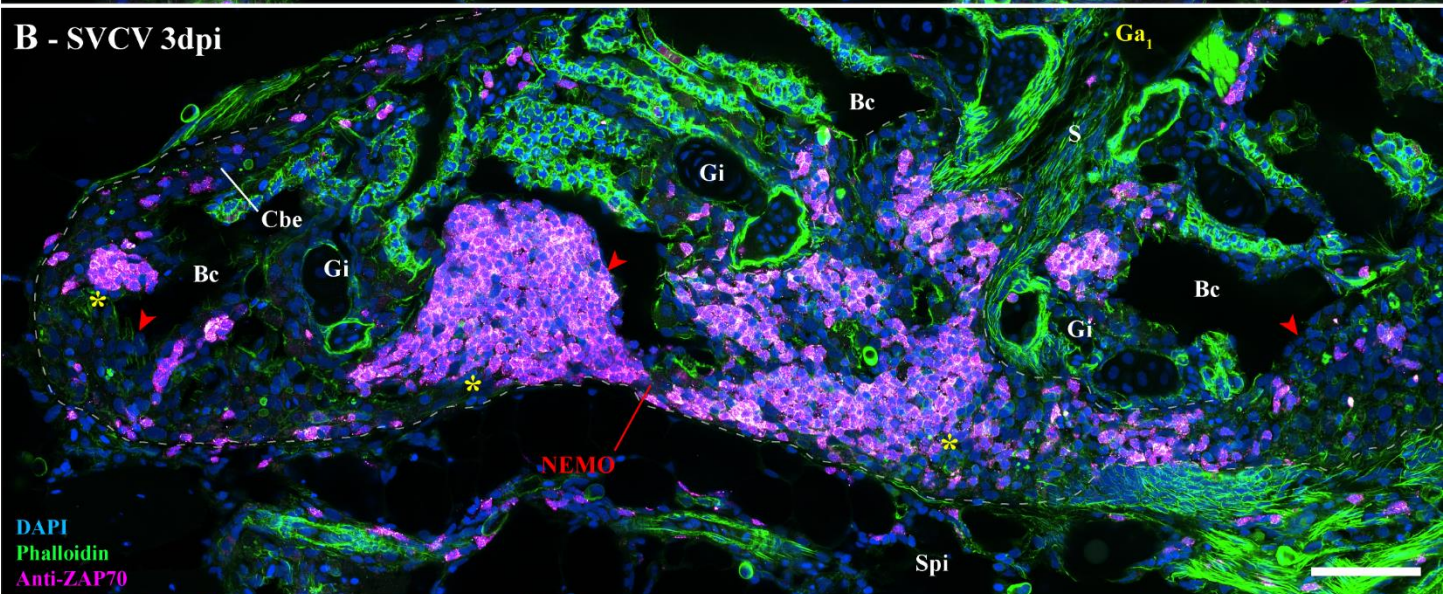
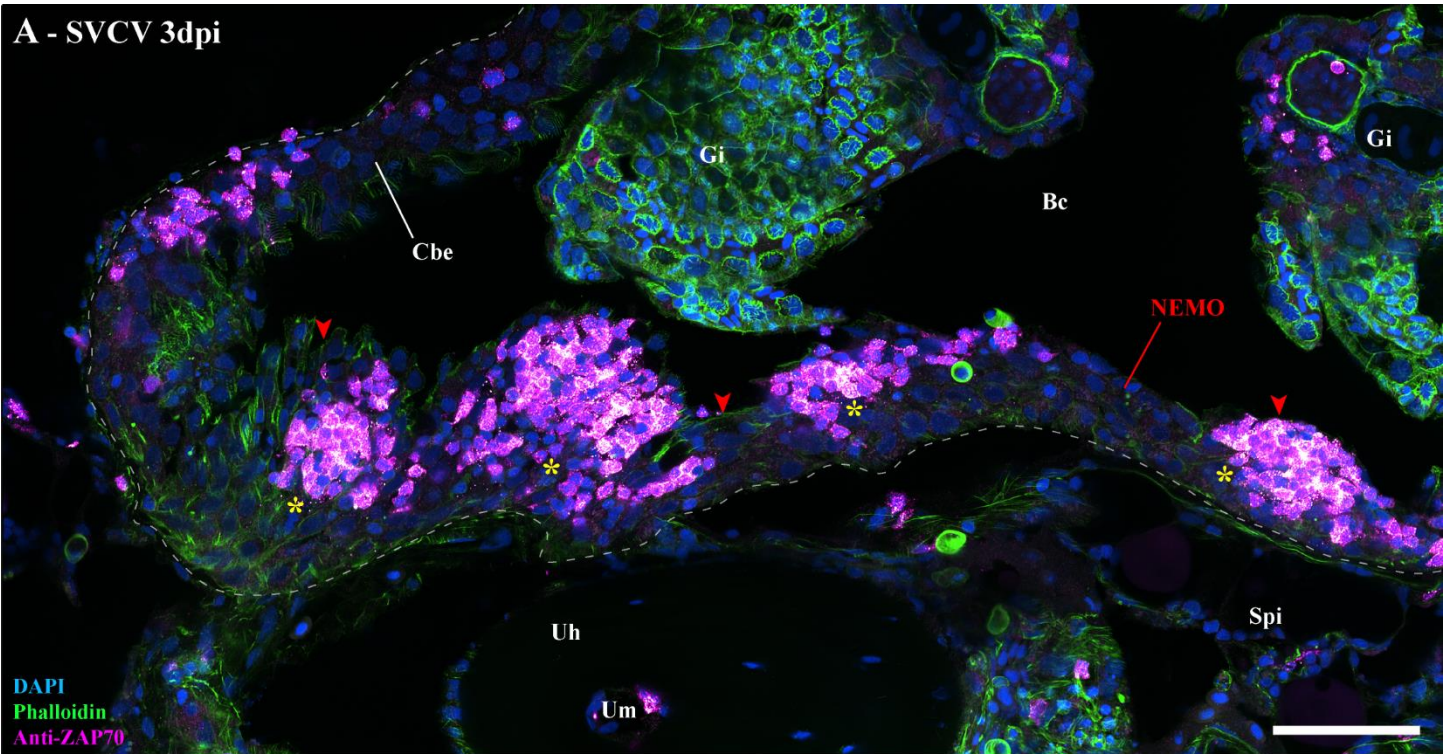


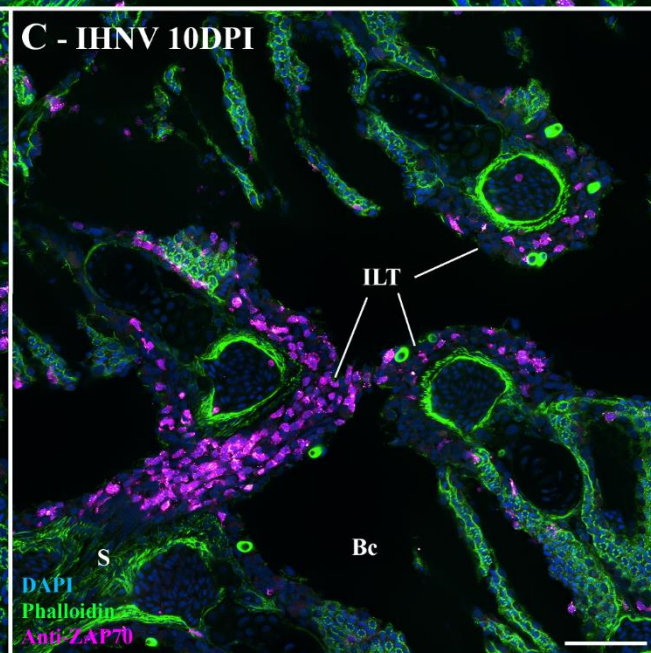
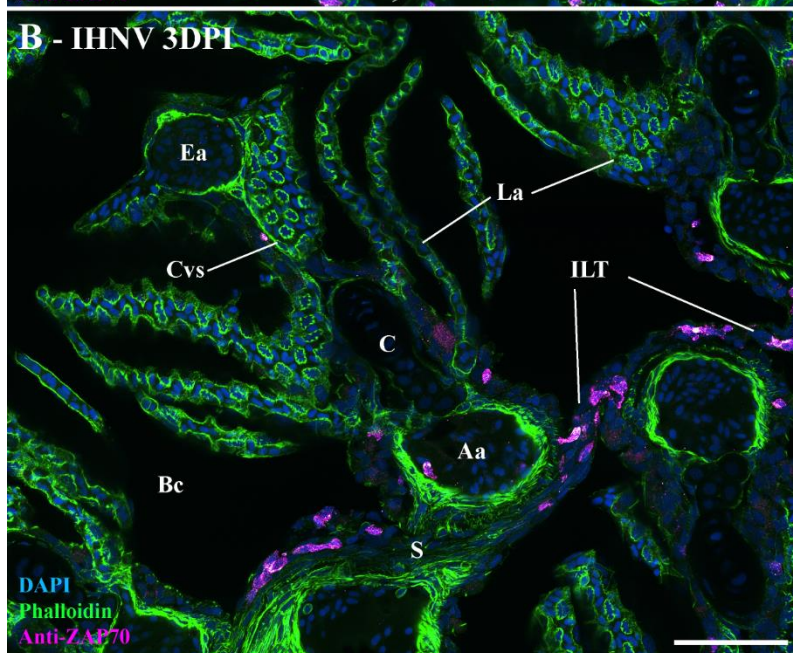
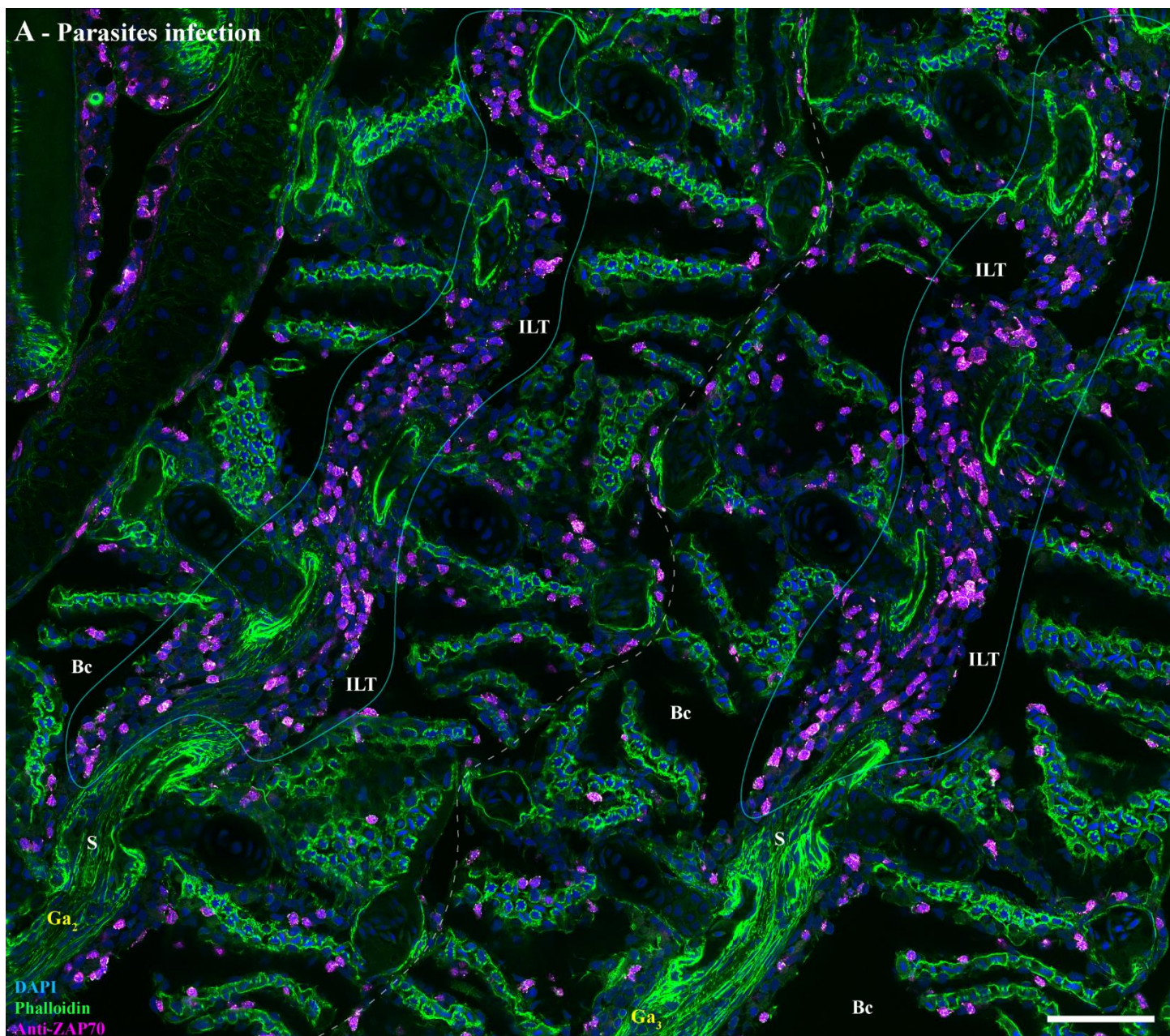
1410
1411

1412 **Figure S7 – Putative plasma/B cells clusters in parasites-infected adult zebrafish.** (A) Cryosection from an adult
1413 zebrafish naturally co-infected with *Pseudoloma neurophilia*, *Pseudocapillaria tomentosa*, and *Myxidium*
1414 *streisingeri*, stained with phalloidin (green) and DAPI (blue), and labeled with anti-BTK antibody (magenta hot).
1415 In addition to putative BTK-positive plasma/B cells in NEMO (red arrowheads), significant clusters of labeled
1416 cells were observed within the connective tissue (cyan star) and associated to endothelial vessels (yellow stars) of
1417 the sub-pharyngeal isthmus. Annotations: Bc, Branchial cavity; Bv, Blood vessel; Ct, Connective tissue; Ev,
1418 Endothelial vessel; Gi, Gills; Spi, Sub-pharyngeal isthmus; Tf, Thyroid follicle and Va, Ventral aorta. Scale bar:
1419 100 μm .

1420
1421
1422
1423
1424
1425
1426
1427
1428
1429
1430
1431

1432 **Figure S8 – Additional images on 3 days post-SVCV infection.** (A-C) Cryosections from adult zebrafish three
1433 days after a 24h bath-infection with SVCV, stained with phalloidin (green) and DAPI (blue), and labeled with anti-
1434 ZAP70 (magenta hot). NEMO (red arrowheads) displayed striking aggregation of T/NK cells into distinct clusters
1435 (yellow stars). Annotations: Bc, Branchial cavity; Cbe, Cavobranchial epithelium; dpi, day post-infection; Gi,
1436 Gills; Spi, Sub-pharyngeal epithelium; SVCV, Spring viremia of carp virus; Uh, Urohyal bone and Um, Urohyal
1437 marrow. Scale bars: 50 μm (A-C).

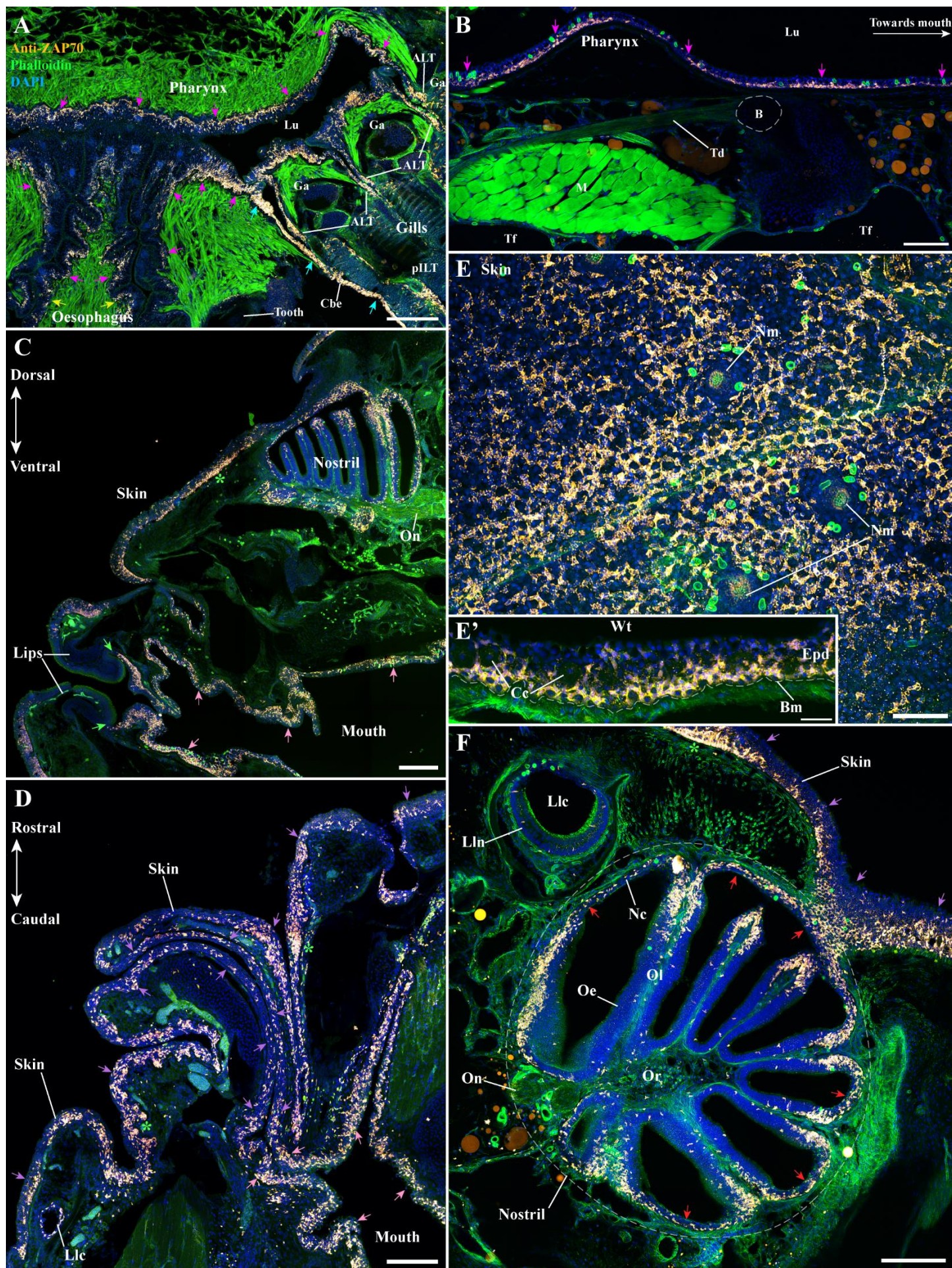




1440 **Figure S9 – Structural response of ILT to viral and parasitic infections.** (A) Cryosections displaying the
1441 interbranchial lymphoid tissue of adult zebrafish naturally co-infected with three parasitic diseases (*Pseudoloma*
1442 *neurophilia*, *Pseudocapillaria tomentosa*, and *Myxidium streisingeri*) stained with phalloidin (green) and DAPI
1443 (blue), and labeled with anti-ZAP70 antibody (magenta hot). The distribution of ZAP70-positive cells is more
1444 scattered than in uninfected fish and displayed small clusters of labeled cells. (B,C) Cryosection displaying the
1445 ILT of an adult zebrafish 3 days (B) and 10 days (C) following a 24h bath-infection with IHNV. Although ILTs
1446 are severely depleted at 3 dpi, they appeared replenished at 10 dpi. Annotations: Aa, Afferent artery; Bc, Branchial
1447 cavity; C, Cartilage; Cvs, Central venous sinus; Ea, Efferent artery; Ga, Gill arch; ILT, Interbranchial lymphoid
1448 tissue; La, Lamellae and S, Septum. Scale bars: 50 μm (A-C).

1449
1450
1451
1452
1453
1454
1455
1456
1457
1458
1459
1460
1461
1462
1463
1464
1465
1466
1467
1468
1469
1470
1471
1472
1473
1474
1475
1476
1477
1478
1479
1480
1481
1482

1483 **Figure S10 – Extension of NEMO's lymphoid network beyond the branchial cavity.** (A-F) Cryosection from
1484 adult zebrafish stained with phalloidin (green) and DAPI (blue), and labeled with anti-ZAP70 (orange hot). (A)
1485 The lymphoid network of the branchial cavity, and which include NEMO, is connected to the pharynx (magenta
1486 arrows) and oesophagus (yellow arrows) via T/NK cell-rich segments of the cavobranial epithelium (cyan
1487 arrows). This lymphoid network is observed along the length of the pharynx (B – magenta arrows) and the mouth
1488 (C,D – pink arrows). Where it is absent from the keratinized lips of the fish (C – green arrows), it connected to the
1489 skin-associated lymphoid tissue (SALT) by the sides of the mouth opening (D - purple arrows). (E) Wholemout
1490 skin of a zebrafish head labeled with anti-ZAP70 and observed from above revealed that the SALT is composed
1491 of a vast network of T/NK cells that are located at the basal layer of the epidermis and between club cells (E')
1492 interspersed by multiple clusters of ZAP70-positive cells (C,D,F – green stars). (F) Via the organization of the
1493 SALT of the scale-less skin of the head, the lymphoid network observed in the branchial cavity is also continuous
1494 with the nasal-associated lymphoid tissue (NALT) (F – red arrows). Annotations: ALT, Amphibranchial lymphoid
1495 tissue; B, Bone; Bm, Basement membrane; Cbe, Cavobranial epithelium; Cc, Club cells; Epd, Epidermis; Ga,
1496 Gill arch; Llc, Lateral line canal; Lln, Lateral line neuromast; Lu, Lumen; pILT, proximal Interbranchial lymphoid
1497 tissue; M, Muscles; Nc, Nasal cavity; Nm, Neuromast; Oe, Olfactory epithelium; Ol, Olfactory lamella; On,
1498 Olfactory nerve; Td, tendon; Tf, Thyroid follicle and Wt, Water. Scale bars: 200 μm (A,C), 150 μm (D,F), 100 μm
1499 (B), 50 μm (E), and 30 μm (E').



1501 **Video S1 – 3D reconstruction: zebrafish NEMO.** Reconstruction of NEMO 3D structure using serial confocal
1502 tomography on a 15 wpf zebrafish head.

1503
1504 **Video S2 – 3D reconstruction: zebrafish branchial cavity region.** Video displaying NEMO (magenta), the
1505 ventral end of gill arches (green), the ALTs (cyan), and the thymus lobes (blue) that have been 3D reconstructed
1506 using serial confocal tomography on 15 wpf zebrafish head.

1507
1508 **Video S3 – 3D reconstruction: Sub-pharyngeal region of a zebrafish branchial cavity.** Video displaying NEMO
1509 (magenta), the ventral end of gill arches (green), the ALTs (cyan), and the thymus lobes (blue) that have been 3D
1510 reconstructed using serial confocal tomography on 15 wpf zebrafish head. A section plane has been included to
1511 highlight the sub-pharyngeal region located at the convergence of the gill arches.

1512
1513 **Video S4 – 3D reconstruction: Localization of NEMO, ALTs, and thymus within a zebrafish head.** Video
1514 displaying NEMO (magenta), the ALTs (cyan), and the thymus lobes (blue) within the head of a 15 wpf zebrafish
1515 labeled with phalloidin (green).

1516
1517 **Video S5 – 3D reconstruction: NEMO reticulated epithelial cell network.** Reconstruction of a NEMO reticulated
1518 epithelial cells network from a cryosection labeled with anti-cytokeratin (red) and DAPI (blue).

1519
1520 **Video S6 – 3D image: Endothelial vessels around zebrafish NEMO.** 3D image from a fli:GFP zebrafish
1521 cryosections, in which endothelial cells are fluorescent (green), stained with phalloidin (red) and DAPI (blue), and
1522 labeled with anti-ZAP70 (white). The video display an anterior region of NEMO wrapped by endothelial vessels.

1523
1524 **Video S7 – 3D reconstruction: shared reticulated epithelial cell network between NEMO and ILT.**
1525 Reconstruction of a NEMO reticulated epithelial cells network from the cryosection labeled with anti-cytokeratin
1526 (red) and DAPI (blue) presented **Fig.S3 A**.

1527
1528 **Video S8 – 3D image: Network of T/NK cells within the scale-less skin of a zebrafish head.** The video displays
1529 the optical sections of a 3D image of the skin covering an adult zebrafish head. The acquisition was obtained from
1530 a wholemount head of zebrafish stained with phalloidin (green), DAPI (blue), and labeled with anti-ZAP70 (red
1531 hot). The optical sections are seen going from the exterior to the interior of the fish.

1532

1533 Supplementary videos are available on figshare: DOI: 10.6084/m9.figshare.22259698
1534 (<https://figshare.com/s/579f756a92ab85922264>)