



HAL
open science

Concepts of Enthesal Pain

Enrico de Lorenzis, Gerlando Natalello, David Simon, Georg Schett, Maria Antonietta d'Agostino

► **To cite this version:**

Enrico de Lorenzis, Gerlando Natalello, David Simon, Georg Schett, Maria Antonietta d'Agostino. Concepts of Enthesal Pain. *Arthritis & rheumatology*, 2023, 75 (4), pp.493-498. 10.1002/art.42299 . hal-04552364

HAL Id: hal-04552364

<https://uvsq.hal.science/hal-04552364v1>

Submitted on 19 Apr 2024

HAL is a multi-disciplinary open access archive for the deposit and dissemination of scientific research documents, whether they are published or not. The documents may come from teaching and research institutions in France or abroad, or from public or private research centers.






L'archive ouverte pluridisciplinaire **HAL**, est destinée au dépôt et à la diffusion de documents scientifiques de niveau recherche, publiés ou non, émanant des établissements d'enseignement et de recherche français ou étrangers, des laboratoires publics ou privés.



Distributed under a Creative Commons Attribution - NonCommercial - NoDerivatives 4.0 International License

REVIEW

Concepts of Enteseal Pain

Enrico De Lorenzis,¹  Gerlando Natalello,¹  David Simon,²  Georg Schett,² 
and Maria Antonietta D'Agostino¹ 

Pain is the main symptom in enteseal diseases (enthesopathies) despite a paucity of nerve endings in the enthesis itself. Eicosanoids, cytokines, and neuropeptides released during inflammation and repeated nonphysiologic mechanical challenge not only stimulate or sensitize primary afferent neurons present in structures adjacent to the enthesis, but also trigger a “neurovascular invasion” that allows the spreading of nerves and blood vessels into the enthesis. Nociceptive pseudounipolar neurons support this process by releasing neurotransmitters from peripheral endings that induce neovascularization and peripheral pain sensitization. This process may explain the frequently observed dissociation between subjective symptoms such as pain and the structural findings on imaging in enteseal disease.

INTRODUCTION

The term “enthesopathy” refers to a disease process that occurs at tendon insertion sites. Enteses are specialized tissues that connect tendons, ligaments, or joint capsules with bones. They can be classified into fibrocartilaginous enteses, which are formed by a layered structure that gradually transforms from tendon fibers to bone, or fibrous enteses, which are characterized by direct insertion through a tissue analog to a tendon or ligament midsubstance (1,2).

Due to their biologic function, enteses are prone to mechanical overuse with subsequent inflammation and tissue remodeling (“degeneration”) accumulating after repeated mechanical stress. Aging, metabolic or hormonal diseases, and specific drugs also facilitate the development of enteseal disease (3). In addition, certain forms of arthritis (i.e., the spondyloarthritis (SpA) disease spectrum, including ankylosing spondylitis, psoriatic arthritis, reactive arthritis, and inflammatory bowel disease [IBD]-associated arthritis) are characterized by the way they preferentially affect the enteses (4). Enteseal disease is characterized by substantial pain that also often occurs in the absence of major structural changes, a phenomenon that is highly clinically relevant but still conceptually poorly explained to date. In this review, we address this feature of enteseal disease

and suggest a mechanistic explanation based on the current evidence.

Pain as the main symptom of enteseal disease

Enteseal disease is associated with a very high pain burden (5). Enteseal pain is the result of a complex relationship between the immune system and the nervous system. Clinical examination of the enteses alone often does not reveal the reason for pain in enteseal disease, making the clinical diagnosis of enteseal disease challenging. Therefore, ultrasound examination and magnetic resonance imaging (MRI) have been used to improve the detection of enteseal disease. Inflammation and structural changes in the enteses have been reported in professional athletes prone to mechanical stress (6,7), as well as in patients with psoriasis (8,9), IBD (10), and SpA (11). Of note, imaging studies have shown that a fraction of asymptomatic individuals in the general population also show signs of enteseal changes on imaging (12). Conversely, enteseal symptoms (e.g., pain) can also occur in the absence of significant imaging findings (13), indicating that enteseal pain does not always need to involve substantial inflammation and/or degeneration. This observation indicates that enteseal pain can result from different processes. Specifically, enteseal pain may be related to a chronic inflammatory

¹Enrico De Lorenzis, MD, Gerlando Natalello, MD, Maria Antonietta D'Agostino, MD, PhD: Division of Rheumatology, Catholic University of the Sacred Heart, Fondazione Policlinico Universitario A. Gemelli IRCCS, Rome, Italy; ²David Simon, MD, Georg Schett, MD: Department of Internal Medicine 3, Friedrich-Alexander University Erlangen-Nurnberg (FAU) and Universitätsklinikum Erlangen, Erlangen, Germany.

Author disclosures are available at <https://onlinelibrary.wiley.com/action/downloadSupplement?doi=10.1002%2Fart.42299&file=art42299-sup-0001-Disclosureform.pdf>.

Address correspondence via email to Maria-Antonietta D'Agostino, MD, PhD, at mariaantonietta.dagostino@unicatt.it.

Submitted for publication March 28, 2022; accepted in revised form July 7, 2022.

process intrinsic to diseases like SpA that is characterized by infiltration of macrophages at the fibrocartilage and by lymphocytes in the corresponding bone marrow (14,15), and/or to a less inflammatory, mechanically induced process (16,17) that only shows spurious signs of inflammation because of repairing mechanisms (18).

Innervation of enthesal tissues and neurovascular response

Microscopic examinations of normal entheses in both humans and animals have shown a paucity of nerve endings in the entheses themselves (19,20). In fact, cartilage-related proteins like aggrecan, which is also a major component of entheses, act as inhibitors of axonal growth (21). In contrast, functionally related structures that surround the entheses (e.g., the fat pad, the paratenon and endotenon, the bone, and the periosteum at the insertion site [22]) are very richly innervated by both small nonmyelinated C and large myelinated A δ nociceptive fibers (23). These nociceptive neurons can be activated as soon as a pathologic process affecting the entheses also affects the surrounding tissues. Enthesal stress is common both in SpA—in which enthesal inflammation is considered a very early abnormality—and upon exacerbated or repeated mechanical stress that often involves the whole tendon or ligament. Moreover, repeated and/or prolonged mechanical challenge and inflammation may trigger a “neurovascular invasion” of the entheses from bone marrow and the adjacent paratenon (24–28). Other pain mechanisms can also be associated with enthesal disease, such as dysfunctional patterns in muscle recruitment (24) or central sensitization associated with both inflammatory (25) and degenerative (26) enthesal diseases.

Prostaglandin E₂ as a mediator in enthesal pain

Despite the high prevalence and intensity of pain in enthesal diseases (26), the actual nociceptive stimuli involved have not yet been fully characterized. Different molecules, such as eicosanoids, cytokines, and neuropeptides, involved in musculoskeletal pathologies can directly stimulate the primary afferent neurons or sensitize them to mechanical stimuli. Therefore, as we will describe below, immune cells in SpA-related enthesitis may not be the exclusive source of algogenic substances, and mesenchymal cells may also play an important role. The specific contribution of mediators is difficult to pinpoint as their biologic signals are widely interconnected and reciprocally amplified (Figure 1).

Given the anatomic and functional background of entheses (27), mechanical strain is consistently deemed a pivotal factor in the pathogenesis of enthesal disease (28), and resident mesenchymal cells are sensitive to changes in load. *In vitro* studies in which cultured mesenchymal cells were used have shown that osteoblasts (29), chondrocytes (30), and fibroblasts (31,32) are mechano-sensitive and produce prostaglandin E₂ (PGE₂) and other inflammation markers (33) in response to repeated stretching. Considering that the entheses are subject to major stress

along the tendon–bone complex (34) and that the production of PGE₂ is stretch-dependent, it can be postulated that the large amounts of PGE₂ are produced locally (35). In this context, PGE₂ production seems to be an event that happens quickly, occurring within hours after mechanical stress and providing the basis for pain and an inflammatory response. Notably, PGE₂ can also promote vasodilation and angiogenesis through the production of vascular endothelial growth factor, the differentiation of bone marrow cells, and the migration of endothelial cells (36).

While the role of immune cells in pain related to degenerative enthesopathies is rather controversial, the specific role of neuronal mediators in proper inflammatory diseases has been marginally addressed (37). PGE₂ is an eicosanoid that can easily cross cell membranes and reach surrounding tissues (38). It is considered an early algogenic mediator that binds receptors on A δ fibers and small C fibers, promoting the activity of the transient receptor potential cation channel V1, P2X₃ purinergic receptors, voltage-gated T-type calcium channels (Ca_v3.2), and the voltage-gated sodium channels Na_v1.8 and Na_v1.9 (39). Moreover, PGE₂ can promote the recruitment of macrophages and T-cells from the bone marrow into the enthesal compartment, which are sources of tumor necrosis factor and interleukin-17, both of which have been shown to amplify pain responses (40–43). The reason the influx of immune cells is more pronounced and prolonged in SpA than in mechanically induced enthesal disease is unclear. This may be due to genetic predisposition as well as barrier changes, such as in the setting of intestinal inflammation, which is characterized by an exaggerated immune response.

Neuropeptides in enthesal pain

Primary nociceptive pseudounipolar neurons can release neurotransmitters from peripheral endings. The term neurogenic inflammation defines the release of mediators that can induce vasodilation, neovascularization, and peripheral pain sensitization (44). Substance P, calcitonin gene-related peptide (CGRP), and glutamate are key mediators of neurogenic inflammation. The role of neurogenic inflammation in enthesal pain has mainly been studied in degenerative enthesal disease. Neuronal sprouting with enhanced expression of substance P and CGRP has been reported in common insertional tendinopathies such as jumper's knee (45), Achilles tendinopathy (46,47), and tennis elbow (48). Findings of animal model studies also suggest that mechanical strain has a role in neurogenic inflammation (49) and that it can lead to a mutual enhancement of PGE₂ and neuropeptides (50).

Similarly, symptomatic degenerative changes in tendon tissue have been associated with high local levels of glutamate (51,52) and higher expression levels of its *N*-methyl-D-aspartate receptor on peripheral nerve ends and on tenocytes themselves (53). Peripheral glutamate and its receptors also play an important role in the activation of nociceptors that are enhanced by substance P (54). The role of neurogenic inflammation in a proper inflammatory disease

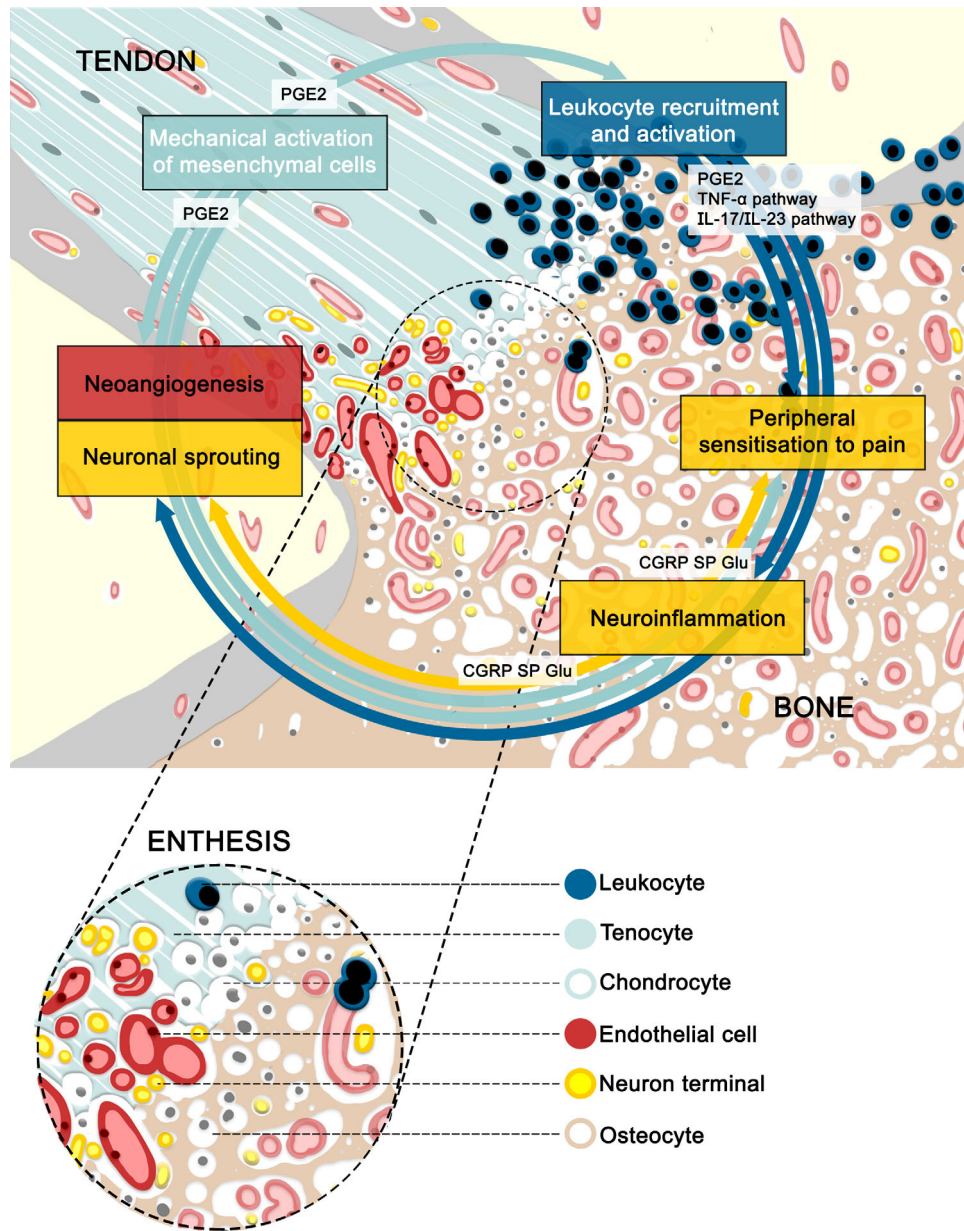


Figure 1. An illustration of the biologic mechanisms occurring in entheses affected by enthesal disease. PGE₂ = prostaglandin E₂; TNF-α = tumor necrosis factor α; IL-17/IL-23 = interleukin-17/interleukin-23; CGRP = calcitonin gene-related peptide; SP = substance P; Glu = glutamate.

such as SpA has not been specifically investigated. However, studies of murine models of inflammatory arthritis have identified nociceptive nerve fibers expressing substance P and CGRP sprouting in the entheses, a finding that is analogous to the observations in models of overuse injuries (55–58).

Anatomic structures involved in enthesal disease

To better understand the relationship between symptoms (pain) and anatomic changes in enthesal disease, imaging of anatomic structures and their respective changes are of seminal

importance. While standardized imaging criteria for mechanically induced enthesal disease are lacking to date, the Outcome Measures in Rheumatology (OMERACT) Ultrasound Working Group has defined inflammatory enthesal disease in the setting of SpA. In ultrasound, such lesions appear as hypoechoic (water-rich) and/or thickened insertions of the tendon close to the bone (a Doppler signal may be present if increased vascularization is exhibited), which may be associated with erosions and bony spurs (enthesophytes) or calcifications (a sign of structural damage) (59). Similarly, the key features of enthesitis on MRI according to the OMERACT MRI Working Group are intratendon hyperintensity (enthesal tendonitis), peritendon hyperintensity

(enthesal peritendinitis), and bone marrow edema (enthesal osteitis), as well as the presence of tendon thickening, enthesophytes, or bone erosions (signs of structural changes) (60). Such alterations have also been described in degenerative enthesal disease, although hypoechoic areas on ultrasound and hyperintensity on MRI may reflect collagen degeneration rather than ongoing inflammation (61), and changes to entheses—including power Doppler signal—are overall more diffuse and distant from the bone compared to enthesal changes seen in inflammatory enthesal disease (62). Also, the degeneration associated with perienthesal osteitis seems to be less extensive compared to the degeneration associated with inflammatory enthesal diseases (63).

Lessons on enthesal pain from imaging studies

Overall, imaging studies have shown that perienthesal tissues are substantially affected by inflammation and structural changes in enthesal disease, providing the basis for pain, as structures such as peritendon tissue, bone, and bone marrow are densely innervated. Moreover, the signal changes in tendons observed on ultrasound and MRI clearly suggest that enthesal disease is associated not only with neovascularization, but also with the reinnervation of previously oligotrophic and highly collagen-rich tissue (turning them into “nociceptive tissues”). Conversely, the paucity of nociceptive nerve fibers at the insertion of healthy tendons supports the observation that early forms of mechanically induced enthesal disease can remain asymptomatic. It can be hypothesized that only later when neurovascular invasion occurs does enthesal disease become symptomatic. Consistent with this concept, it has been shown that the presence of subclinical enthesal disease predicts the onset of articular symptoms in patients with psoriasis (64) or chronic overuse related to sport activities (65). Moreover, imaging studies have shown that signs of neoangiogenesis are specifically associated with pain in mechanically induced enthesal disease (66–68), while the findings from an imaging study by Feydy et al on inflammatory enthesal disease were inconclusive with regard to the relationship (69).

The idea that eicosanoids such as PGE₂ have a role in the process of neoangiogenesis in enthesal disease is supported by the evidence that nonsteroidal antiinflammatory drugs (NSAIDs) dampen the detection of vascular signals in contrast-enhanced ultrasonography (70). It is therefore not surprising that NSAIDs are the first choice of treatment for both inflammatory and degenerative forms of enthesal disease (71).

Conclusions

Taken together, these findings suggest that pain in the context of enthesal disease is triggered by the involvement of well-innervated perienthesal structures, as well as by a neurovascular

response that leads to the spreading of blood vessels and nerves into the oligotrophic tissues of the tendon and the entheses. Future research should focus more closely on the relationship between symptoms and anatomic structures involved in enthesal disease by utilizing both imaging techniques and biopsy-based histopathologic examinations of the enthesal structures affected by vascularization and innervation. The apparent dissociation between anatomic changes and clinical symptoms may be linked to the different underlying mechanisms leading to enthesal disease in inflammatory and mechanically induced musculoskeletal conditions. Mechanically induced enthesal disease may initially be asymptomatic because the extent of innervation and vascularization at the affected enthesis is not severe enough to produce symptoms. This silent phase of the disease may facilitate the accrual of further damage and ultimately lead to perienthesal involvement and a neurovascular response that allows for the transition to symptomatic disease. Conversely, inflammatory enthesal disease involves periarticular tissues early in the disease course and therefore becomes symptomatic at an early stage, triggering fast neurovascular responses. After the cessation of inflammation, this neurovascular invasion of the enthesis persists, thereby triggering pain as well as a higher sensitivity to the recurrence of inflammation, explaining the “uncoupling” of pain from structural changes in the affected enthesis.

AUTHOR CONTRIBUTIONS

All authors drafted the article, revised it critically for important intellectual content, and approved the final version to be published.

ACKNOWLEDGMENT

Open Access Funding provided by Universita Cattolica del Sacro Cuore within the CRUI-CARE Agreement.

REFERENCES

1. Benjamin M, Kumai T, Milz S, et al. The skeletal attachment of tendons—tendon “entheses”. *Comp Biochem Physiol A Mol Integr Physiol* 2002;133:931–45.
2. Shaw HM, Benjamin M. Structure-function relationships of entheses in relation to mechanical load and exercise. *Scand J Med Sci Sports* 2007;17:303–15.
3. Slobodin G, Rimar D, Boulman N, et al. Enthesal involvement in systemic disorders. *Clin Rheumatol* 2015;34:2001–10.
4. Shaw HM, Benjamin M. Structure-function relationships of entheses in relation to mechanical load and exercise. *Scand J Med Sci Sports* 2007;17:303–15.
5. D’Agostino MA, Palazzi C, Olivieri I. Enthesal involvement. *Clin Exp Rheumatol* 2009;27 Suppl:S50–5.
6. Kulig K, Oki KC, Chang YJ, et al. Achilles and patellar tendon morphology in dancers with and without tendon pain. *Med Probl Perform Art* 2014;29:221–8.
7. Visnes H, Tegnander A, Bahr R. Ultrasound characteristics of the patellar and quadriceps tendons among young elite athletes. *Scand J Med Sci Sports* 2015;25:205–15.

8. Tang Y, Yang Y, Xiang X, et al. Power doppler ultrasound evaluation of peripheral joint, entheses, tendon, and bursa abnormalities in psoriatic patients: a clinical study. *J Rheumatol* 2018;45:811–7.
9. Offidani A, Cellini A, Valeri G, et al. Subclinical joint involvement in psoriasis: magnetic resonance imaging and x-ray findings. *Acta Derm Venereol* 1998;78:463–5.
10. Rovisco J, Duarte C, Batticcioto A, et al. Hidden musculoskeletal involvement in inflammatory bowel disease: a multicenter ultrasound study. *BMC Musculoskelet Disord* 2016;17:241.
11. D'Agostino MA, Aegerter P, Bechara K, et al. How to diagnose spondyloarthritis early? Accuracy of peripheral enthesitis detection by power Doppler ultrasonography. *Ann Rheum Dis* 2011;70:1433–40.
12. Bakirci S, Solmaz D, Stephenson W, et al. Enteseal changes in response to age, body mass index, and physical activity: an ultrasound study in healthy people. *J Rheumatol* 2020;47:968–72.
13. Balint PV, Kane D, Wilson H, et al. Ultrasonography of enteseal insertions in the lower limb in spondyloarthropathy. *Ann Rheum Dis* 2002;61:905–10.
14. McGonagle D, Marzo-Ortega H, O'Connor P, et al. Histological assessment of the early enthesitis lesion in spondyloarthropathy. *Ann Rheum Dis* 2002;61:534–7.
15. Laloux L, Voisin MC, Allain J, et al. Immunohistological study of entheses in spondyloarthropathies: comparison in rheumatoid arthritis and osteoarthritis. *Ann Rheum Dis* 2001;60:316–21.
16. Alfredson H, Forsgren S, Thorsen K, et al. In vivo microdialysis and immunohistochemical analyses of tendon tissue demonstrated high amounts of free glutamate and glutamate NMDAR1 receptors, but no signs of inflammation, in Jumper's knee. *J Orthop Res* 2001;19:881–6.
17. Dean BJ, Dakin SG, Millar NL, et al. Emerging concepts in the pathogenesis of tendinopathy [review]. *Surgeon* 2017;15:349–54.
18. Jomaa G, Kwan CK, Fu SC, et al. A systematic review of inflammatory cells and markers in human tendinopathy. *BMC Musculoskelet Disord* 2020;21:78.
19. Rufai A, Ralphs JR, Benjamin M. Structure and histopathology of the insertional region of the human Achilles tendon. *J Orthop Res* 1995;13:585–93.
20. Shaw HM, Santer RM, Watson AH, et al. Adipose tissue at entheses: the innervation and cell composition of the retromalleolar fat pad associated with the rat Achilles tendon. *J Anat* 2007;211:436–43.
21. Snow DM, Letourneau PC. Neurite outgrowth on a step gradient of chondroitin sulfate proteoglycan (CS-PG). *J Neurobiol* 1992;23:322–36.
22. Spang C, Alfredson H. Richly innervated soft tissues covering the superficial aspect of the extensor origin in patients with chronic painful tennis elbow—implication for treatment? *J Musculoskelet Neuronal Interact* 2017;17:97–103.
23. Palesy PD. Tendon and ligament insertions—a possible source of musculoskeletal pain. *Cranio* 1997;15:194–202.
24. Sterling M, Jull G, Wright A. The effect of musculoskeletal pain on motor activity and control. *J Pain* 2001;2:135–45.
25. Ulutatar F, Unal-Ulutatar C, Duruoaz MT. Fibromyalgia in patients with psoriatic arthritis: relationship with enthesopathy, sleep, fatigue and quality of life. *Int J Rheum Dis* 2020;24:183–8.
26. Plinsinga ML, Brink MS, Vicenzino B, et al. Evidence of nervous system sensitization in commonly presenting and persistent painful tendinopathies: a systematic review. *J Orthop Sports Phys Ther* 2015;45:864–75.
27. Slobodin G, Rozenbaum M, Boulman N, et al. Varied presentations of enthesopathy. *Semin Arthritis Rheum* 2007;37:119–26.
28. Jacques P, McGonagle D. The role of mechanical stress in the pathogenesis of spondyloarthritis and how to combat it. *Best Pract Res Clin Rheumatol* 2014;28:703–10.
29. Sanuki R, Mitsui N, Suzuki N, et al. Effect of compressive force on the production of prostaglandin E and its receptors in osteoblastic Saos-2 cells. *Connect Tissue Res* 2007;48:246–53.
30. Gosset M, Berenbaum F, Levy A, et al. Mechanical stress and prostaglandin E2 synthesis in cartilage. *Biorheology* 2008;45:301–20.
31. Yang G, Im HJ, Wang JH. Repetitive mechanical stretching modulates IL-1 β induced COX-2, MMP-1 expression, and PGE2 production in human patellar tendon fibroblasts. *Gene* 2005;363:166–72.
32. Wang JH, Jia F, Yang G, et al. Cyclic mechanical stretching of human tendon fibroblasts increases the production of prostaglandin E2 and levels of cyclooxygenase expression: a novel in vitro model study. *Connect Tissue Res* 2003;44:128–33.
33. Thorpe CT, Chaudhry S, Lei II, et al. Tendon overload results in alterations in cell shape and increased markers of inflammation and matrix degradation. *Scand J Med Sci Sports* 2015;25:e381–91.
34. Thomopoulos S, Williams GR, Gimbel JA, et al. Variation of biomechanical, structural, and compositional properties along the tendon to bone insertion site. *J Orthop Res* 2003;21:413–9.
35. Bergqvist F, Carr AJ, Whewy K, et al. Divergent roles of prostacyclin and PGE2 in human tendinopathy. *Arthritis Res Ther* 2019;21:74.
36. Zhang Y, Daaka Y. PGE2 promotes angiogenesis through EP4 and PKA ζ pathway. *Blood* 2011;118:5355–64.
37. Bring DK, Heidgren ML, Kreicbergs A, et al. Increase in sensory neuropeptides surrounding the Achilles tendon in rats with adjuvant arthritis. *J Orthop Res* 2005;23:294–301.
38. Schuster VL. Molecular mechanisms of prostaglandin transport. *Ann Rev Physiol* 1998;60:221–42.
39. Kawabata A. Prostaglandin E2 and pain—an update. *Biol Pharm Bull* 2011;34:1170–3.
40. Alaaeddine N, Di Battista JA, Pelletier JP, et al. Inhibition of tumor necrosis factor α -induced prostaglandin E2 production by the anti-inflammatory cytokines interleukin-4, interleukin-10, and interleukin-13 in osteoarthritic synovial fibroblasts: distinct targeting in the signaling pathways. *Arthritis Rheum* 1999;42:710–8.
41. Paulissen SM, van Hamburg JP, Davelaar N, et al. Synovial fibroblasts directly induce Th17 pathogenicity via the cyclooxygenase/prostaglandin E2 pathway, independent of IL-23. *J Immunol* 2013;191:1364–72.
42. Cook AD, Christensen AD, Tewari D, et al. Immune cytokines and their receptors in inflammatory pain. *Trends Immunol* 2018;39:240–55.
43. Lee KM, Zhang Z, Achuthan A, et al. IL-23 in arthritic and inflammatory pain development in mice. *Arthritis Res Ther* 2020;22:123.
44. Basbaum AI, Bautista DM, Scherrer G, et al. Cellular and molecular mechanisms of pain. *Cell* 2009;139:267–84.
45. Sanchis-Alfonso V, Roselló-Sastre E, Subías-Lopez A. Neuroanatomic basis for pain in patellar tendinosis (“jumper’s knee”): a neuroimmunohistochemical study. *Am J Knee Surg* 2001;14:174–7.
46. Andersson G, Danielson P, Alfredson H, et al. Nerve-related characteristics of ventral paratendinous tissue in chronic Achilles tendinosis. *Knee Surg Sports Traumatol Arthrosc* 2007;15:1272–9.
47. Schubert TE, Weidler C, Lerch K, et al. Achilles tendinosis is associated with sprouting of substance P positive nerve fibres. *Ann Rheum Dis* 2005;64:1083–6.
48. Ljung BO, Forsgren S, Fridén J. Substance P and calcitonin gene-related peptide expression at the extensor carpi radialis brevis muscle origin: implications for the etiology of tennis elbow. *J Orthop Res* 1999;17:554–9.
49. Backman LJ, Andersson G, Wennstig G, et al. Endogenous substance P production in the Achilles tendon increases with loading in an in vivo model of tendinopathy-peptidergic elevation preceding tendinosis-like tissue changes. *J Musculoskelet Neuronal Interact* 2011;11:133–40.

50. Vasko MR, Campbell WB, Waite KJ. Prostaglandin E2 enhances bradykinin-stimulated release of neuropeptides from rat sensory neurons in culture. *J Neurosci* 1994;14:4987–97.
51. Alfredson H, Forsgren S, Thorsen K, et al. In vivo microdialysis and immunohistochemical analyses of tendon tissue demonstrated high amounts of free glutamate and glutamate NMDAR1 receptors, but no signs of inflammation, in Jumper's knee. *J Orthop Res* 2001;19:881–6.
52. Alfredson H, Forsgren S, Thorsen K, et al. Glutamate NMDAR1 receptors localised to nerves in human Achilles tendons. Implications for treatment? *Knee Surg Sports Traumatol Arthrosc* 2001;9:123–6.
53. Schizas N, Lian O, Frihagen F, et al. Coexistence of up-regulated NMDA receptor 1 and glutamate on nerves, vessels and transformed tenocytes in tendinopathy. *Scand J Med Sci Sports* 2010;20:208–15.
54. Zhang Q, Zhao Y, Guo Y, et al. Electrophysiological evidence for the interaction of substance P and glutamate on A δ and C afferent fibre activity in rat hairy skin. *Clin Exp Pharmacol Physiol* 2006;33:1128–33.
55. O'Connor TM, O'Connell J, O'Brien DI, et al. The role of substance P in inflammatory disease. *J Cell Physiol* 2004;201:167–80.
56. Messner K, Wei Y, Andersson B, et al. Rat model of Achilles tendon disorder. A pilot study. *Cells Tissues Organs* 1999;165:30–9.
57. Bring DK, Heidgren ML, Kreicbergs A, et al. Increase in sensory neuropeptides surrounding the Achilles tendon in rats with adjuvant arthritis. *J Orthop Res* 2005;23:294–301.
58. O'Connor TM, O'Connell J, O'Brien DI, et al. The role of substance P in inflammatory disease. *J Cell Physiol* 2004;201:167–80.
59. Balint PV, Terslev L, Aegerter P, et al. Reliability of a consensus-based ultrasound definition and scoring for enthesitis in spondyloarthritis and psoriatic arthritis: an OMERACT US initiative. *Ann Rheum Dis* 2018;77:1730–5.
60. Mathew J, Krabbe S, Eshed I, et al. The OMERACT MRI in enthesitis initiative: definitions of key pathologies, suggested MRI sequences, and a novel heel enthesitis scoring system. *J Rheumatol* 2019;46:1232–8.
61. Khan KM, Bonar F, Desmond PM, et al. Patellar tendinosis (jumper's knee): findings at histopathologic examination, US, and MR imaging. Victorian Institute of Sport Tendon Study Group. *Radiology* 1996;200:821–7.
62. D'Agostino MA, Terslev L. Imaging evaluation of the entheses: ultrasonography, MRI, and scoring of evaluation. *Rheum Dis Clin North Am* 2016;42:679–93.
63. McGonagle D, Marzo-Ortega H, O'Connor P, et al. The role of biomechanical factors and HLA-B27 in magnetic resonance imaging-determined bone changes in plantar fascia enthesopathy. *Arthritis Rheum* 2002;46:489–93.
64. Naredo E, Möller I, de Miguel E, et al. High prevalence of ultrasonographic synovitis and enthesopathy in patients with psoriasis without psoriatic arthritis: a prospective case-control study. *Rheumatology (Oxford)* 2011;50:1838–48.
65. Splittgerber LE, Ihm JM. Significance of asymptomatic tendon pathology in athletes. *Curr Sports Med Rep* 2019;18:192–200.
66. Zanetti M, Metzdorf A, Kundert HP, et al. Achilles tendons: clinical relevance of neovascularization diagnosed with power Doppler US. *Radiology* 2003;227:556–60.
67. Palaniswamy V, Ng SK, Manickaraj N, et al. Relationship between ultrasound detected tendon abnormalities, and sensory and clinical characteristics in people with chronic lateral epicondylalgia. *PLoS One* 2018;13:e0205171.
68. Cook JL, Malliaras P, De Luca J, et al. Neovascularization and pain in abnormal patellar tendons of active jumping athletes. *Clin J Sport Med* 2004;14:296–9.
69. Feydy A, Lavie-Brion MC, Gossec L, et al. Comparative study of MRI and power Doppler ultrasonography of the heel in patients with spondyloarthritis with and without heel pain and in controls. *Ann Rheum Dis* 2012;71:498–503.
70. Mouterde G, Aegerter P, Correas JM, et al. Value of contrast-enhanced ultrasonography for the detection and quantification of enthesitis vascularization in patients with spondyloarthritis. *Arthritis Care Res (Hoboken)* 2014;66:131–8.
71. Gossec L, Baraliakos X, Kerschbaumer A, et al. EULAR recommendations for the management of psoriatic arthritis with pharmacological therapies: 2019 update. *Ann Rheum Dis* 2020;79:700–12.